

ENETS Consensus Guidelines for the Standards of Care in Neuroendocrine Tumors: Echocardiography

Ursula Plöckinger^a Björn Gustafsson^b Diana Ivan^c Waldemar Szpak^d
Joseph Davar^e and all other Mallorca Consensus Conference participants

^aDepartment of Hepatology and Gastroenterology, Campus Virchow-Klinikum, Charité-Universitätsmedizin Berlin, Berlin, Germany; ^bMedisinsk avd Gastroseksjon, St Olavs Hospital HF, Trondheim, Norway; ^cEndocrinology and Diabetology, Klinikum der Philipps-Universität, Marburg, Germany; ^dWestville Hospital, Amanzimototi, Mayville, South Africa; ^eDepartment of Cardiology, Royal Free Hospital, London, UK

Introduction

Carcinoid heart disease is observed in 3–4% of all patients with a neuroendocrine tumor and in 40–50% of those with a carcinoid syndrome [1, 2]. Details on well-differentiated neuroendocrine jejunal-ileal tumors have already been discussed in the ENETS Consensus Guidelines and the reader is referred to these Guidelines [3]. Here technical questions and quality management for the diagnosis and follow-up of carcinoid heart disease will be discussed.

Involvement of the tricuspid leaflets grade 2–3 occurs in 90%, a stenosis of the pulmonary leaflets in 50%, while regurgitation is seen in 81% of the patients during the course of the disease [4, 5]. Carcinoid heart disease is a relatively late manifestation of neuroendocrine tumors; however, it has an important impact on the prognosis of these patients. Thus, early diagnosis and treatment is mandatory in each patient with a carcinoid syndrome. Echocardiography is the gold standard for detection of carcinoid heart disease. This article will concentrate on technical details for echocardiography. The information provided should help those not experienced with this disease to diagnose carcinoid heart disease and provide high-quality information of echocardiographic investi-

gations. The information provided by echocardiography will be the basis for clinical decisions and may well influence the prognosis and outcome of the patient.

What Are the Characteristics of Carcinoid Heart Disease?

There are specific characteristic features of carcinoid heart disease, such as thickening of valvular leaflets, valvular cups and chordae. Due to these changes, there is reduced excursion of the valvular leaflets, cups and chordae. In addition, retracted, shortened and fixed leaflets or cups can be observed. These changes may subsequently lead to valvular regurgitation and/or stenosis, resulting in right ventricular dilatation and reduced function, as well as right atrial dilatation.

Technological Requirements for Echocardiography and Documentation

As a basic standard equipment for high-quality echocardiography, a midrange platform with the ability to perform two-dimensional, color-coded pulsed-wave and

continuous-wave Doppler investigations is needed. The optimal recommended equipment could be a high-end platform with the ability to perform stress echocardiography, transoesophageal echocardiography, three-dimensional echocardiography, tissue Doppler echocardiography and investigations with transpulmonary contrast agents. Visualization should be electrocardiographically triggered. Multiple frequency imaging technology is recommended for the transducers. Digital documentation of all images, as well as computerized documentation of images and reports, is recommended.

Patient Information for Optimal Cooperation

For optimal cooperation, adequate information should be provided to the patient. Thus, the patient should be informed that:

(1) Transthoracic echocardiography is a painless investigation in which three leads are attached to the chest of the patient for ECG and a probe is placed on the chest to scan the heart with ultrasound.

(2) In order to detect the possibility of a patent foramen ovale which would allow for vasoactive substances to be transferred from the right side of the heart to the left side and cause damage to left-sided valves, a 'bubble' study should be performed. During the study, saline – 'salt water' – mixed with a very small amount of the patient's blood is injected into the left antecubital vein and the patient should then be asked to perform 'cough' and 'Valsalva' manoeuvres.

In addition, in those patients who are considered candidates for surgical therapy, transoesophageal echocardiography and possibly cardiac catheterization should be performed. Transoesophageal echocardiography is an investigation of the valves and pumping chambers of the heart performed with an ultrasound transducer placed at the tip of the thin tube. The tube is swallowed by the patient and is located in the gullet during the procedure. The investigation could be performed with or without light sedation.

Necessary Information to Be Provided before Echocardiographic Investigations

The interpretation of results as well as the estimation of disease progress may be influenced by previous therapies, i.e. thoracic surgery, as well as by previous echocardiographic results. Thus, detailed information on previous therapies and echocardiographic results should be provided.

How Should the Investigation Be Performed?

Routine standards of echocardiographic investigations should be followed. Thus, the patient is placed in a left decubitus position. Echocardiographic views are acquired as per recommendation of the respective societies (for example according to the recommendations of the American Society for Echocardiography or the British Society for Echocardiography) [6–8]. For better assessment of pulmonary and tricuspid valves, a high long-axis parasternal view of the pulmonary valve and modified parasternal view of the right ventricular inflow are useful. In addition, assessment of the left ventricular size and function are an integral part of the echocardiographic investigation of patients with neuroendocrine tumors.

As the assessment of patency of the foramen ovale is a necessary part of the initial evaluation of the patient with confirmed diagnosis of carcinoid heart disease, the recommended procedure is described in detail as follows:

A 20- to 22-gauge Abbocath is placed into the antecubital vein and connected to a three-way tap. Two Luer lock 10-ml syringes are attached to the three-way tap. One of the syringes is filled with 8 ml of saline; 0.3 ml of blood is withdrawn from the vein into the syringe; 0.2 ml of air is added to the 'mixture'. Saline, blood and 0.2 ml of air are mixed between 2 Luer lock syringes attached to the three-way tap on the arm of the patient. 3–4 ml of the agitated mixture is injected as a bolus into the vein under ultrasound control and with continuous recording of images. The injection should be repeated under cough and Valsalva manoeuvre (release phase). A patent foramen ovale is considered present when there is a transfer of microbubbles from the right atrium to the left atrium within 3–5 cardiac cycles.

Echocardiographic Report

The echocardiographic report should give details on special features of the valves, like thickening of the leaflets, reduction of mobility of the leaflets, retraction of the leaflets, maximal degree of the reduction of mobility. The report should indicate if the leaflets are fixed. In addition, the following special features of the endocardium should be mentioned:

- Occasional visualization of fibrous plaques of the endocardium, together with functional data like wall motion and overall function of the right as well as the left ventricle.

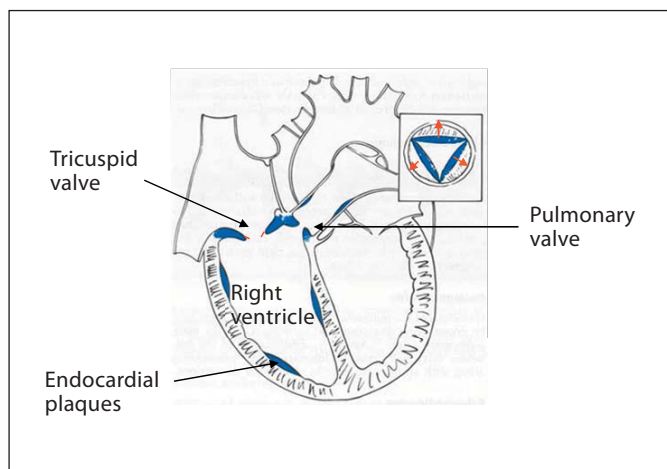


Fig. 1. Carcinoid heart disease.

- Wall thickness assessment is an integral part of conventional echocardiographic investigation. Right ventricular size should be assessed in a four-chamber view as per ASE recommendation.
- Ejection fraction of the right ventricle is difficult to assess due to the complex geometry of the right ventricle. If available, three-dimensional echocardiography is a promising tool. Meanwhile, right ventricular function assessment is semiquantitative. Fractional shortening could also be used as per ASE recommendation.

To allow for ‘proper’ follow-up echocardiography, description of thickness, mobility, ‘shape’ of the valve leaflets, presence and degree of shortening and retraction, assessment of degree of regurgitation as well as of degree of stenosis, size and function of the ventricles have to be provided and digital storage of all examinations is mandatory (fig. 1).

To avoid pitfalls in the echocardiographic evaluation of neuroendocrine tumors, utmost attention to the degree of ‘brightness’ of different parts of the valvular apparatus and to the degree of mobility of the leaflets/cusps of the valves is necessary, as a minor degree of involvement is very easy to miss.

Personal experience in echocardiography with at least 200 examinations per year is recommended for those evaluating patients with carcinoid heart disease.

List of Participants

List of Participants of the Consensus Conference on the ENETS Guidelines for the Standard of Care for the Diagnosis and Treatment of Neuroendocrine Tumors, Held in Palma de Mallorca (Spain), November 28 to December 1, 2007

Göran Åkerström, Department of Surgery, University Hospital, Uppsala (Sweden); Bruno Annibale, University Sapienza Roma, Rome (Italy); Rudolf Arnold, Department of Internal Medicine, Philipps University, Munich (Germany); Emilio Bajetta, Medical Oncology Unit B, Istituto Nazionale Tumori, Milan (Italy); Jaroslava Barkmanova, Department of Oncology, University Hospital, Prague (Czech Republic); Yuan-Jia Chen, Department of Gastroenterology, Peking Union Medical College Hospital, Chinese Academy of Medical Sciences, Beijing (China); Frederico Costa, Hospital Sirio Libanes, Centro de Oncologia, São Paulo (Brazil); Anne Couvelard, Service de Gastroentérologie, Hôpital Beaujon, Clichy (France); Wouter de Herder, Department of Internal Medicine, Section of Endocrinology, Erasmus MC, Rotterdam (The Netherlands); Gianfranco Delle Fave, Ospedale S. Andrea, Rome (Italy); Barbro Eriksson, Medical Department, Endocrine Unit, University Hospital, Uppsala (Sweden); Massimo Falconi, Medicine and Surgery, University of Verona, Verona (Italy); Diego Ferone, Departments of Internal Medicine and Endocrinological and Metabolic Sciences, University of Genoa, Genoa (Italy); David Gross, Department of Endocrinology and Metabolism, Hadassah University Hospital, Jerusalem (Israel); Ashley Grossman, St. Bartholomew’s Hospital, London (UK); Rudolf Hyrdel, II. Internal Medical Department, University Hospital Martin, Martin (Slovakia); Gregory Kaltsas, G. Genimatas Hospital, Athens (Greece); Reza Kianmanesh, UFR Bichat-Beaujon-Louis Mourier, Service de Chirurgie Digestive, Hôpital Louis Mourier, Colombes (France); Günter Klöppel, Institut für Pathologie, TU München, Munich (Germany); Ulrich-Peter Knigge, Department of Surgery, Rigshospitalet, Copenhagen (Denmark); Paul Komminoth, Institute for Pathology, Stadtspital Triemli, Zürich (Switzerland); Beata Kos-Kudła, Slaska Akademia Medyczna Klinika Endokrynologii, Zabrze (Poland); Dik Kwekkeboom, Department of Nuclear Medicine, Erasmus University Medical Center, Rotterdam (The Netherlands); Rachida Lebtahi, Nuclear Medicine Department, Bichat Hospital, Paris (France); Val Lewington, Royal Marsden, NHS Foundation Trust, Sutton (UK); Anne Marie McNicol, Division of Cancer Sciences and Molecular Pathology, Pathology Department, Royal Infirmary, Glasgow (UK); Emmanuel Mitry, Hepatogastroenterology and Digestive Oncology, Hôpital Ambroise-Paré, Boulogne (France); Ola Nilsson, Department of Pathology, Sahlgrenska sjukhuset, Gothenburg (Sweden); Kjell Öberg, Department of Internal Medicine, Endocrine Unit, University Hospital, Uppsala (Sweden); Juan O’Connor, Instituto Alexander Fleming, Buenos Aires (Argentina); Dermot O’Toole, Department of Gastroenterology and Clinical Medicine, St. James’s Hospital and Trinity College Dublin, Dublin (Ireland); Ulrich-Frank Pape, Department of Internal Medicine, Division of Hepatology and Gastroenterology, Campus Virchow-Klinikum, Charité-Universitätsmedizin Berlin, Berlin (Germany); Mauro Papotti, Department of Biological and Clinical Sciences, University of Turin/St. Luigi Hospital, Turin (Italy); Marianne Pavel, Department of Hepatology and Gastroenterology, Campus Virchow-Klinikum,

Charité-Universitätsmedizin Berlin, Berlin (Germany); *Aurel Perren*, Institut für Allgemeine Pathologie und Pathologische Anatomie der Technischen Universität München, Klinikum r.d. Isar, Munich (Germany); *Marco Platania*, Istituto Nazionale dei Tumori di Milano, Milan (Italy); *Guido Rindi*, Department of Pathology and Laboratory Medicine, Università degli Studi, Parma (Italy); *Philippe Ruszniewski*, Service de Gastroentérologie, Hôpital Beaujon, Clichy (France); *Ramon Salazar*, Institut Català d'Oncologia, Barcelona (Spain); *Aldo Scarpa*, Department of Pathology, University of Verona, Verona (Italy); *Klemens Scheidhauer*, Klinikum rechts der Isar, TU München, Munich (Ger-

many); *Jean-Yves Scoazec*, Anatomie Pathologique, Hôpital Edouard-Herriot, Lyon (France); *Anders Sundin*, Department of Radiology, Uppsala University Hospital, Uppsala (Sweden); *Babs Taal*, Netherlands Cancer Centre, Amsterdam (The Netherlands); *Pavel Vitek*, Institute of Radiation Oncology, University Hospital, Prague (Czech Republic); *Marie-Pierre Vullierme*, Service de Gastroentérologie, Hôpital Beaujon, Clichy (France); *Bertram Wiedenmann*, Department of Internal Medicine, Division of Hepatology and Gastroenterology, Campus Virchow-Klinikum, Charité-Universitätsmedizin Berlin, Berlin (Germany).

References

- 1 Norheim I, et al: Malignant carcinoid tumors. An analysis of 103 patients with regard to tumor localization, hormone production, and survival. *Ann Surg* 1987;206:115–125.
- 2 Makridis C, et al: Progression of metastases and symptom improvement from laparotomy in midgut carcinoid tumors. *World J Surg* 1996;20:900–907.
- 3 Eriksson B, et al: Consensus guidelines for the management of patients with digestive neuroendocrine tumors – well-differentiated jejunal-ileal tumor/carcinoma. *Neuroendocrinology* 2008;87:8–19.
- 4 Pellikka PA, et al: Carcinoid heart disease. Clinical and echocardiographic spectrum in 74 patients. *Circulation* 1993;87:1188–1196.
- 5 Jacobsen MB, et al: Cardiac manifestations in mid-gut carcinoid disease. *Eur Heart J* 1995;16:263–268.
- 6 ACC/AHA/ASE 2003 guideline uptake for the clinical application of echocardiograph: summary article. *J Am Soc Echocardiogr* 2003;16:1091–1110.
- 7 Chambers J, Masani N, Hancock J, Graham J, Wharton G, Ionescu A: Minimum dataset for a standard adult transthoracic echocardiogram. *British Society of Echocardiography* (access date 20.6.08). http://www.bsecho.org/index.php?option=com_docman&task=cat_view&gid=36&&Itemid=61.
- 8 Hoffmann R: Positionspapier zu Qualitätsstandards in der Echokardiographie. *Z Kardiol* 2004;93:975–986.