

Consensus Guidelines for the Management of Patients with Digestive Neuroendocrine Tumours: Well-Differentiated Tumour/Carcinoma of the Appendix and Goblet Cell Carcinoma

Ursula Plöckinger^a Anne Couvelard^b Massimo Falconi^c Anders Sundin^d
Ramon Salazar^e Emanuel Christ^f Wouter W. de Herder^g David Gross^h
Wolfram H. Knappⁱ Ulrich P. Knigge^j Matthew H. Kulke^k
Ulrich F. Pape^l all other Frascati Consensus Conference participants¹

^aCharité Universitätsmedizin, Campus Virchow-Klinikum, Department of Hepatology and Gastroenterology, Berlin, Germany; ^bHôpital Beaujon, Service de Gastroenterologie, Clichy, France; ^cUniversity of Verona, Medicine and Surgery, General Surgery Section, MED/18 – General Surgery, Verona, Italy; ^dUppsala University Hospital, Department of Radiology, Uppsala, Sweden; ^eInstitut Català d'Oncologia, Barcelona, Spain; ^fEndokrinologie für Erwachsene, Inselspital, Bern, Switzerland; ^gDepartment of Internal Medicine, Section of Endocrinology, Erasmus MC, Rotterdam, The Netherlands; ^hDepartment of Endocrinology & Metabolism, Hadassah University Hospital, Jerusalem, Israel; ⁱMHH, Klinik für Nuklearmedizin, Hannover, Germany; ^jDepartment of Surgery, C2122, Rigshospitalet Blegdamsvej, Copenhagen, Denmark; ^kDana-Farber Cancer Institute, Boston, Mass., USA; ^lCharité Universitätsmedizin, Department of Internal Medicine, Division of Hepatology and Gastroenterology, Campus Virchow Klinikum, Berlin, Germany

© Free Author Copy – for personal use only

ANY DISTRIBUTION OF THIS ARTICLE WITHOUT WRITTEN CONSENT FROM S. KARGER AG, BASEL IS A VIOLATION OF THE COPYRIGHT.

Written permission to distribute the PDF will be granted against payment of a permission fee, which is based on the number of accesses required. Please contact permission@karger.ch

Endocrine Tumour of the Appendix

Definition

Endocrine tumours of the appendix are defined [1] as either: (1) well-differentiated endocrine tumour with benign or uncertain behaviour; (2) well-differentiated endocrine carcinoma, or (3) goblet cell carcinoma, synonymous to adenocarcinoid or mucinous adenocarcinoid. The first part of these guidelines deals with well-differentiated appendiceal endocrine tumours/carcinomas, the second part with goblet cell carcinomas.

U. Plöckinger wrote Part 1 and R. Salazar Part 2; the entire paper was revised by U. Plöckinger according to comments and suggestions from A. Couvelard, M. Falconi and A. Sundin; they and the other authors listed in alphabetical order equally contributed to the preparation of the Guidelines.

Part 1: Appendiceal Endocrine Tumour

Epidemiology and Clinicopathological Features

Epidemiology

The clinical incidence of appendiceal endocrine tumours is 2–3/million/year with a 2:1 preference for female sex, but no preference for race [2–8]. The overall peak incidence occurs at 15–19 years in female patients and at 20–24 years in male patients. In contrast to these data, the SEER database, compiling only malignant tumours, gives an incidence for malignant appendiceal tumours of 0.63/million/year for the years 1973–2001 [9], a peak incidence at 38–49 years and a preferential occurrence in the white population compared to the African-American, Hispanic or Asian population [6, 9].

¹ See list at the end of the paper.

Appendiceal endocrine tumours are the second most frequently occurring gastrointestinal endocrine tumours with a relative frequency of 30–25%. If only malignant tumours are considered, moreover, they are third in frequency (17%), after tumours of the small intestine (45%) and the rectum (20%) [6].

Endocrine appendiceal tumours make up to 35–85% of all appendiceal neoplasms [10–12]. They are serendipitously diagnosed in 3–9 of 1,000 appendectomies [13–16]. Thus, at an estimated 100 appendectomies per year in a community hospital, even smaller institutions will see at least one appendiceal endocrine tumour per year [16].

Minimal Consensus Statement on Epidemiology

Appendiceal endocrine tumours occur with an incidence of 2–3/million/year. They are diagnosed more often in female, while there is no overall difference for race. In contrast, malignant tumours occur more often in Caucasians compared to other races.

Symptoms

The patient may present with pain in the right lower abdomen or right testis. However, as most of these tumours are diagnosed incidentally, they are not closely related to a specific clinical presentation. The diagnosis is associated with, but not related to, acute appendicitis, as most appendiceal endocrine tumours are located at the tip of the appendix (62–78%) and thus tumour-induced luminal obstruction does not play a role in the pathogenesis of appendicitis [15–17]. Benign pelvic surgery or even cholecystectomy may as well lead to the diagnosis of appendiceal endocrine tumours [13]. It has been suggested that the incidence of appendiceal endocrine tumours is higher in females because they more often undergo surgery. However, even if this is taken into account, there is still a female preponderance [4, 18, 19]. The association with a carcinoid syndrome is extremely rare and is estimated to occur in less than 1%. As with most endocrine tumours, the autoptic prevalence is high with 9–170/100,000 [13, 16].

Minimal Consensus Statement on Symptoms

Appendiceal endocrine tumours are diagnosed incidentally during appendectomy and association with a carcinoid syndrome is rare and does only occur in tumours with widespread disease.

Clinicopathological Assessment

The WHO classification [1] gives the well-known scheme for endocrine tumours: 1.1. Well-differentiated endocrine tumour with benign behaviour, non-functioning, confined to the appendiceal wall, with a maximal diameter ≤ 2 cm and without angioinvasion; 1.2. Well-differentiated endocrine tumour with uncertain behaviour, non-functioning, confined to the subserosa, maximal diameter > 2 cm or with angioinvasion; 2. Well-differentiated endocrine carcinoma (malignant carcinoid) of low-grade malignancy, invading the mesoappendix or beyond, and/or with metastases.

Classes 1.2 and 2 suggest an increased risk of malignancy or a reduced life expectancy, respectively. Thus, proper classification is important and influences therapeutic decisions. Therefore, evidence relating tumour characteristics, like size of the tumour, location, invasive behaviour and proliferation to prognostic data, will be discussed to allow for informed decisions.

Size. Data from the SEER database (1973–2001) give the distribution of malignant appendiceal endocrine tumours among all malignant appendiceal tumours according to size. 15% of tumours < 1 cm, 19% between 1 and 2 cm, and 7% > 2 cm are endocrine tumours [9]. As the SEER data refer only to malignant tumours, they underestimate the percentage of well-differentiated endocrine appendiceal tumours < 1 cm.

Including all appendiceal tumours the distribution is 60–80% for those < 1 cm, 4–37% for those 1–2 cm and 2–17% for those > 2 cm [11, 15–17]. Metastatic disease at the time of diagnosis is clearly related to the size of the tumour and has not been observed in tumours < 1 cm, and is very rarely observed in tumours with a maximum diameter > 1 cm but < 2 cm. Patients with a tumour diameter of < 1 –2 cm have a very low risk ($< 1\%$) for progressive disease. Most incidences of progressive disease with a size below < 2 cm have been published as case reports. Looking at the data from tumours with regional lymph node metastases, only 10% of these tumours were between 1 and 2 cm and all other metastatic tumours had larger diameters [20]. In their review of the literature, Thirlby et al. [20] found no death after appendectomy, no tumour recurrence nor any distant metastases in tumours with a maximal diameter ≤ 2 cm, while a size > 2 cm has been reported to negatively influence the 5-year survival rate in the series drawn from the SEER database [9]. Moertel et al. [15] reported metastatic disease in 7/21 (31%) of patients with tumours > 2 cm.

Accordingly, prognosis is related to the size of the tumour and most patients with appendiceal endocrine tu-

Table 1. Prognosis of appendiceal endocrine tumours according to size

Author	Median follow-up	All patients	Metastases	Patients	<2 cm	<2 cm + mesoappendiceal invasion	>2 cm + mesoappendiceal invasion
Stinner and Rothmund [16]	n.i.	493	neg pos	476 17	361 0 (0%)	75 5 (6.7%)	40 12 (30%)
					<1 cm	>1 and <2 cm	>2 and <3 cm
Moertel et al. [15]	26 years	150	neg pos	143 7	104 0 (0%)	23 0 (0%)	11 3 (21%)
							≥3 cm
							4 (44%)

mours have a favourable prognosis (table 1), as the number of tumours diagnosed with a size >2 cm is rather low.

Location. Most appendiceal endocrine tumours are located at the tip of the appendix (60–75%), with 5–21% and 7–10% localized at mid-appendix or the base of the appendix [11, 15–17]. Patients with an appendiceal endocrine tumour located at the tip of the appendix are probably cured by appendectomy. There are no data to estimate the influence of tumour location at mid-third of the appendix on survival. Location at the base of the appendix may confer a somewhat higher risk of recurrence after appendectomy. Again, no reliable data are available on this subgroup of already rare tumours. However, location at the base of the appendix may change the therapeutic decision, if there is an additional involvement of the surgical margins or the caecum [21].

Multicentricity of the tumour is rare and has not been observed in the largest series so far [15]. However, associated carcinoids of the small bowel or rectum have been observed. In these cases, the clinical picture was dominated by the non-appendiceal lesions and the appendiceal tumours were incidental findings [15].

Invasion. Mesoappendiceal involvement of appendiceal endocrine tumours can be demonstrated in 30–40% of children and 10–20% of adults [11, 17, 22]. Invasion of the serosa is not correlated with lymph node metastases and has no impact on survival, while invasion of the mesoappendix may progress to lymphatic metastases in <1% of patients [23, 24]. Interestingly, there was no discernable difference between metastatic and non-metastatic disease in cellular morphology or architecture [15]. However, mesoappendiceal invasion and vascular invasion was observed more often in those with metastases than in patients without metastasis (table 1). On the other

hand, mesoappendiceal invasion occurs frequently and has been observed in 33–57% of appendiceal endocrine tumours [23, 24]. Rossi et al. [25] investigated 15 appendiceal endocrine tumours <2 cm and found mesoappendiceal invasion in all tumours. None of their patients treated with simple appendectomy developed metastatic disease during a mean follow-up of 52.6 months. The very thorough analysis by Moertel et al. [15] traced 86 patients for >10 years, with individual follow-up extending to 36 years. In their group, 7% of the patients had lesions at the base of the appendix and 64% had involvement of the mesoappendix or the peritoneum. In no instance did a patient have recurrent or metastatic disease following simple appendectomy. In contrast, MacGillivray et al. [26] reviewed 414 cases of appendiceal endocrine tumours reported in the literature. According to their analysis, both tumours >2 cm and mesoappendiceal invasion were related to metastatic disease. However, metastases were reported in only 17 (4.1%) of the 414 cases, reports were individual case reports, thus statistical analysis was problematic and the overall generalized significance of this finding questionable. Therefore, for now, the impact of mesoappendiceal on survival is still controversial. The proposed TNM classification for appendiceal endocrine tumours [47] separate minimal (≤ 3 mm) from large (>3 mm) mesoappendiceal invasion, the former being an equivalent to subserosal invasion [Rindi et al., in press, 2007]. This TNM classification allows for minimal mesoappendiceal invasion of tumours ≤ 2 cm (T2), while a diameter >2 cm and/or mesoappendiceal invasion >3 mm classifies the tumour as T3.

Malignant behaviour is related to tumour invasion of the vasculature at diagnosis. Vascular invasion has a 30% risk of lymph node metastases, but negatively influences

survival [16]. However, microscopic vascular invasion has to be demonstrated by immunohistochemical analysis, as the high frequency of angioinvasion reported might actually be related to tissue artefacts rather than true neoplastic vascular involvement [25].

Proliferation. There are no data including the proliferation marker Ki-67 or the number of mitosis as prognostic indicators in well-differentiated appendiceal endocrine carcinomas.

Minimal Consensus Statement on Clinicopathological Features

Size, i.e. a maximal diameter ≥ 2 cm, is the single most important parameter for prognosis. Metastatic disease in patients with tumours ≤ 2 cm is rare. Most tumours (70%) are located at the tip of the appendix. There are no data indicating that location at the mid-third or the base of the appendix confers a less favourable prognosis. Subserosal invasion and microscopic lymphatic invasion have no influence on the overall prognosis, while data are not so unequivocal for mesoappendiceal invasion. The influence of proliferation markers is still unclear.

Synchronous or Metachronous Neoplasia

Patients with appendiceal endocrine tumours have a significant risk for synchronous or metachronous neoplasia. This has been reported to be as high as 29% [15] and includes not only gastrointestinal malignancies but breast, cervix, endometrial cancer and other neoplasia. Thus, lifelong screening for additional malignant tumours should be performed in these patients.

Prognosis

Most patients with appendiceal endocrine tumours have a favourable prognosis. Appendiceal endocrine tumours < 2 cm confined to the appendix wall are cured by appendectomy. Mesoappendiceal invasion in tumours < 2 cm has no negative effect on survival [25]. Deep mesoappendiceal invasion may slightly increase the risk of metastatic behaviour. However, data are still conflicting. Location at the base of the appendix, with involvement of the surgical margins or the caecum, may as well indicate an uncertain malignant potential. According to the SEER database, for patients with malignant disease 5-year survival is 83% for all stages, 94% for those with localized disease, 83% for regional disease manifestation, and 31% for those with distant disease [9, 15, 26, 27].

Minimal Consensus Statement on Prognosis

From the available data it can be deduced that an appendiceal endocrine tumour, at any location, a size ≤ 2 cm, with invasion up to the subserosa or mesoappendiceal invasion up to 3 mm, poses no further risk after appendectomy. On the other hand, size > 2 cm or deep mesoappendiceal invasion or margin invasion confer a relevant risk of recurrence and further surgical procedures are warranted.

Diagnostic Procedures

As most appendiceal tumours are detected incidentally during or after appendectomy, only diagnostic procedures for follow-up have to be discussed. The following procedures have been consented upon.

Imaging

Primary diagnosis of appendiceal endocrine tumours by CT is rare, due to the small size of the tumour, the confinement to the distal part of the appendix and the low complication rate of the tumours [28]. Thus, imaging is used for follow-up, to diagnose recurrence or metastatic disease. For appendiceal tumours ≤ 2 cm, treated by appendectomy and without any sign of malignancy, no further examinations are required after surgery. For well-differentiated tumours > 2 cm, at all locations of the appendix, imaging follow-up is recommended by contrast-enhanced multiphase CT and somatostatin receptor scintigraphy including SPECT or, if available CT-SPECT or PET-CT (using ^{68}Ga -labelled somatostatin analogue as the tracer). MRT has been discussed as being probably less effective than CT. In addition, colonoscopy or colon CT (with neutral enema) has been suggested to diagnose possible synchronous tumours. Follow-up has to be lifelong, as recurrence has been seen > 20 years after diagnosis [15].

Biochemistry

Chromogranin A can be used as tumour marker in appendiceal endocrine tumours and is useful to differentiate the tumour from goblet cell carcinoids. It is indicated in metastatic disease as a biochemical parameter for follow-up. In the rare patient with carcinoid syndrome, 5-hydroxyindol acetic-acid (5-HIAA) is useful. To avoid falsely elevated 5-HIAA, proper proceedings with 24-hour urine collection and food and/or medical restrictions during the collecting period should be adhered to.

Neither germline testing nor somatic tumour DNA investigations are recommended, nor is genetic counselling, as appendiceal endocrine tumours are sporadic tumours and not related to familial tumour syndromes.

Histopathology

Histopathological examination of the specimen is recommended according to standard procedures with hematoxylin and eosin, chromogranin A and synaptophysin immunohistochemistry and assessment of the mitotic index (mitosis per high-power field) and Ki-67 index. Tumour subtyping by immunohistochemistry is not necessary on a routine basis but can be used for differential diagnosis. There is no need of immunostaining for p53 or somatostatin receptors subtype 2A. A TNM classification and grading scheme has been suggested and should be routinely used.

Minimal Consensus Statement on Diagnostic Procedures for Follow-Up

For well-differentiated tumours, diagnosed incidentally, with a maximum diameter <1 cm and R0 resection, no follow-up is required. For well-differentiated tumours of 1 to <2 cm and R0 resection there are no sufficient data for a clear-cut decision. Most participants of the consensus conference suggested that no follow-up is required. However, in cases with deep mesoappendiceal infiltration or angioinvasion, CT of the abdomen and somatostatin receptor scintigraphy may be performed. Factors believed to argue for follow-up investigations are a high proliferation marker, vascular involvement, deep mesoappendiceal infiltration, and possibly location at the base of the appendix.

Surgical Therapy

Appendiceal tumours can be cured by appendectomy if the tumour is located at the tip of the appendix, the tumour diameter is ≤ 2 cm and no deep mesoappendiceal invasion is observed [15]. More aggressive surgical therapy, i.e. right hemicolectomy, is indicated if any of the following is present: tumour diameter >2 cm, deep mesoappendiceal invasion, and/or positive surgical margins [29, 30].

Whether location at the base of the appendix justifies right hemicolectomy is still controversial. Most participants suggested adhering to the above criteria, independent of the location of the tumour. As right hemicolectomy can pose a risk in elderly patients (morbidity up to 40%, with respiratory and cardiovascular complications), and appendectomy is an adequate treatment for patients with appendiceal endocrine tumours ≤ 2 cm, decisions

for a more aggressive treatment based on the location of the tumours should be individualized and are generally not justified. However, re-intervention should be performed if there are positive or unclear margins in this situation. Timing of the hemicolectomy should be within 3 months after appendectomy and can safely be performed by laparoscopic approach. There are no data to support that a two-step approach may negatively affect the prognosis. Thus, in case of doubt at the time of the first procedure, waiting for final pathological assessment is acceptable. This is important, as during routine appendectomies neither experience with neuroendocrine tumours, nor pathological frozen examination may be available (fig. 1).

In advanced, metastatic appendiceal tumours, strategies as applied for colonic rectal tumours are recommended, with an even more aggressive scheme for those tumours with only local or regional metastases. Liver metastases are treated according to the standard procedures (guidelines for intestinal neuroendocrine carcinomas). However, experience is lacking due to the rare occurrence of these tumours.

Minimal Consensus Statement on Therapy

Most participants agreed that a well-differentiated appendiceal tumour ≤ 2 cm is cured by appendectomy independent of the location of the tumour. Thus, right hemicolectomy is justified only in those rare tumours <2 cm, but with positive or unclear margins or with deep mesoappendiceal invasion. Tumours with a diameter >2 cm should be treated by right hemicolectomy.

Medical Therapy

No medical therapy is indicated in patients with resected appendiceal endocrine tumours who are considered cured. In patients with metastatic disease an approach like that to endocrine tumours of the jejunum or ileum has been suggested. Chemotherapeutic options are not available on an evidence-based level, nor are data to recommend peptide radioreceptor therapy (PRRT). PRRT may be an option in a somatostatin receptor-positive, metastasized, inoperable appendiceal endocrine tumour. In this rare setting, PRRT has to be considered investigational.

Minimal Consensus Statement on Medical Therapy

No standard medical therapy is available for metastatic disease. If medical therapy has to be considered the suggested approach should follow the guidelines for endocrine tumours of the jejunum or ileum.

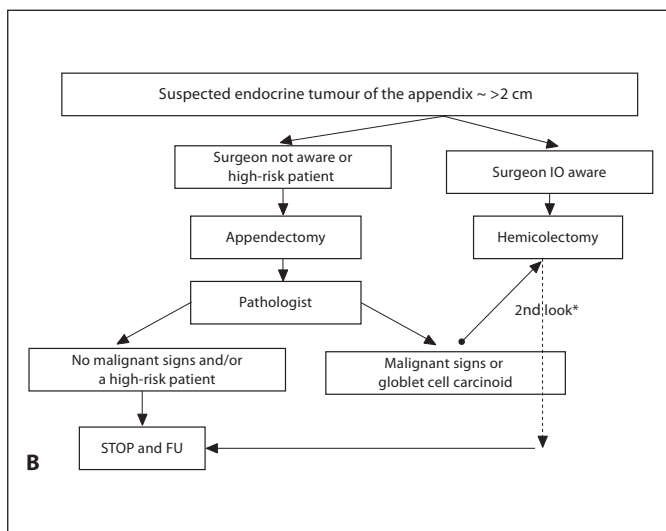
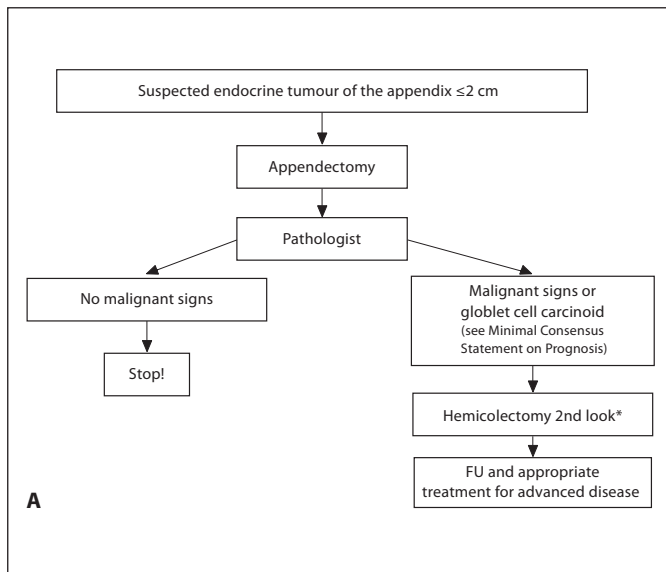


Fig. 1. Therapeutic algorithm for suspected endocrine tumours of the appendix. * Within 3 months from the 1st operation. FU = Follow-up; IO = intraoperative.

Follow-Up

In patients considered cured after surgical therapy, either by appendectomy or right hemicolectomy, and without metastatic disease, one chromogranin A determination, 6–12 months postoperatively, has been suggested. In the rare patient with a functional tumour, 5-HIAA should be added to the biochemical follow-up.

For all other patients with appendiceal endocrine tumours, follow-up (clinical, biochemical and imaging)

should be performed after 6 and 12 months, followed by yearly investigations. In these patients, follow-up has to be lifelong.

In addition, cancer screening is recommended in all patients due to the high coincidence (7–48%) of meta- or synchronous tumours in these patients.

Minimal Consensus Statement on Follow-Up

Follow-up for patients considered cured is not justified and only one CgA determination 6–12 months postoperatively has been suggested. All other patients should be investigated 6 and 12 months postoperatively and then yearly. Follow-up has to be performed lifelong.

Part 2: Goblet Cell Carcinoids of the Appendix

Introduction

Goblet cell carcinoids (GCC) are a distinct clinical and pathologic entity with variable but certain malignant potential, developed from a pluripotent cell of the appendix with divergent neuroendocrine and mucinous differentiation. Adenocarcinoids, goblet cell tumours, or mucinous adenocarcinoids are all synonymous terms of GCC. They have a more aggressive natural history than classical appendiceal endocrine tumours and thus require a different diagnostic and therapeutic approach.

Epidemiology and Clinicopathological Features

Epidemiology

The incidence rate of GCC is 0.05/100,000/year (SEER 1973–2001) [9]. This figure is only slightly lower than appendiceal endocrine tumours (0.63/1,000,000/year) in the SEER database. However, this observation is biased, as this survey considers only ‘malignant’ appendiceal tumours which, in the case of appendiceal endocrine tumours, may account for less than 5% of the cases (Swedish Family Cancer Database) [4]. The incidence of GCC is estimated to be one-tenth of that for appendiceal endocrine tumours. GCC are considered a distinct entity of appendiceal tumours [4, 31] and occur in 0.3–0.9% of appendectomies. They comprise 35–58% of all appendiceal neoplasm. Median age at presentation is the fifth decade, with a second peak at 70 years. This is 20–40 years later than the age peak for classical appendiceal endocrine tumours. There is no sex preference, in contrast to appen-

diceal endocrine tumours. The majority of patients are white Caucasians. GCC are not associated with hormonal hyperfunction [4, 6, 7, 9, 32].

Minimal Consensus Statement on Epidemiology

GCC are rare appendiceal tumours, which must be differentiated from appendiceal endocrine tumours. They occur during the fifth decade, more often in the Caucasian population than any other race, with an equal distribution between the sexes.

Clinicopathological Assessment

In the last version of the WHO classification of endocrine tumours, GCC were classified as mixed exocrine-endocrine carcinoma along with other, low-grade, malignant tumours [1].

Clinical Presentation

Goblet cell tumours usually manifest as acute appendicitis, or less commonly with chronic symptoms associated with a pelvic mass at presentation. These tumours have a median size moderately smaller than appendiceal endocrine tumours and staging favours local tumours by 60% (table 2). This is not remarkably different from appendiceal endocrine tumours in the SEER database [9]. However, these data underestimate the percentage of appendiceal endocrine tumours <1 cm because they do not account for benign appendiceal endocrine tumours. The clinical presentation of GCC relates to the most frequent localization of these tumours. Appendiceal endocrine tumours are mostly located at the tip of the appendix and thus are unlikely to cause appendicitis. Diagnosis of appendiceal endocrine tumours is therefore incidental. In contrast, GCC are usually located in the mid-third of the appendix and may well cause appendiceal obstruction. This can result in signs and symptoms of acute appendicitis. Concomitant distant metastases are present at diagnosis in 11% of the patients. Most metastases are located in the ovaries, followed by disseminated abdominal carcinomatosis and extra-abdominal sites. Synchronous or metachronous diagnosis of second malignancies is not an uncommon finding, with a particularly high rate of colonic cancers [9, 13, 17, 32–34].

Minimal Consensus Statement on Clinical Presentation

Most GCC, when located in the mid-third of the appendix, may cause appendicitis. At diagnosis, 11% of these tumours are already widespread with distant metastases to the ovaries and the peritoneum.

Table 2. Size and stage of goblet cell carcinoid and appendiceal endocrine tumours at presentation (SEER 1973–2001) [data from ref. 9]

Histology	Size ≤1 cm	Size >1 to ≤2 cm	Size >2 cm
AET	15%	19%	7%
GCC	47%	26%	11%
	Localized	Regional	Distant
AET	60%	28%	12%
GCC	64%	24%	12%

AET = Appendiceal endocrine tumour; GCC = goblet cell carcinoid.

Prognosis

GCC bear a remarkably worse prognosis than appendiceal endocrine tumours, with a 5-year survival rate of 76% compared to 83%, respectively. Survival correlates well with stage. Advanced GCC with distant metastases have a poor prognosis, similar to that of other malignant appendiceal tumours like mucinous and signed-ring cell adenocarcinoma. Table 3 gives 5-year survival rates for appendiceal endocrine tumours and GCC by stage. Size also correlates with survival, when analysed by the following cut-off points: <1 cm, between 1 and 2 cm and >2 cm [9]. Other prognostic factors are serosal involvement, invasion of the mesoappendix or extension to adjacent organs or peritoneum. Mesoappendiceal involvement was observed in 51% of pathological specimens in a series of 227 patients (SEER 1973–1998). In contrast to appendiceal endocrine tumours, serosal involvement was also of prognostic value, and was, together with mesoappendiceal invasion, more predictive of outcome than lymph node status. Lymph node status was positive in a low percentage of cases and was therefore not a good positive predictive value indicator [18].

Clinicopathological classification of GCC should be defined within an independent category, different from other low-grade, malignant mixed exocrine-endocrine carcinoma. Clinicopathological classification should include the size categories defined for appendiceal endocrine tumours (<1/1–2/>2 cm), due to the different risk of regional and distant metastases in these three size categories. Thus, a TNM classification is proposed that differentiates T1 into T1a (<1 cm); T1b (1–2 cm). Reported 5-year survival rates for localized, regional and distant stages at diagnosis of 64, 24, and 12%, respectively, are in line with the personal experience of the consensus con-

Table 3. Five-year survival rates of goblet cell carcinoid and appendiceal endocrine tumours by stage (SEER 1973–2001) [data from ref. 9]

Stage	AET	GCC
All stages	83%	18%
Localized	94%	55%
Regional	83%	21%
Distant	31%	7%

AET = Appendiceal endocrine tumour; GCC = goblet cell carcinoid.

ference participants. Advanced GCC are likely as aggressive as adenocarcinomas of the colon.

Minimal Consensus Statement on Clinical Presentation and Prognosis

Most patients present with acute appendicitis, or alternatively with chronic lower right abdominal pain. Involvement of the mesoappendix is observed in approximately half of the cases. GCC have a remarkably worse outcome compared to appendiceal endocrine tumours, even when adjusted for well-recognized prognostic factors like size and stage.

Diagnostic Procedures

Imaging

GCC tumours are diagnosed as a result of an appendectomy, mostly in the context of an episode of acute appendicitis. Diagnostic investigations are therefore performed after the first therapy (appendectomy). CT and MRI have similar sensitivity, and both are superior to abdominal ultrasound (US). Somatostatin receptor scintigraphy (SRS) has the highest sensitivity in detecting endocrine neoplastic residual disease and soft tissue metastases in the abdomen [35, 36]. For liver metastases, results of different studies show a high sensitivity with all four imaging techniques. The degree of variability depends on the specific technology used in each study. One study showed slight superiority of SRS and US over CT with a sensitivity of 90, 88 and 78%, respectively [36]. In a more recent study, the number of detected metastases was significantly higher with MRI than with CT and SRS and higher with CT than with SRS [37]. Other options, if available, are CT-SPECT (contrast-enhanced, multiphase CT combined with somatostatin receptor scintigraphy-SPECT) or CT-PET with a ⁶⁸Ga-labelled soma-

tostatin analogue. These new techniques are supposed to be more sensitive than conventional imaging, as indicated by the results of a recent comparison in 84 patients with various NETs [38]. In this study, PET with ⁶⁸Ga-labelled octreotide was more sensitive and as specific as SRS whereas CT was more sensitive than SRS but less specific. However, evidenced-based data are still lacking in this respect.

All patients should be asked to undergo repeated colonoscopy or, if available, colon CT (with neutral enema) for screening of synchronous or metachronous tumours [33, 39].

Biochemistry

The recommended biochemical tests in patients with GCC differ from those with appendiceal endocrine tumours because no specific endocrine markers have been observed. Thus, CgA or any other determination of a neuroendocrine hormone or neurotransmitter is not recommended. In metastatic disease, epithelial markers and others, related to the mucinous component or the peritoneal invasiveness of GCC, like CEA, CA-19-9, CA-125, are to be performed initially and followed periodically.

Minimal Consensus Statement on Imaging and Biochemistry

Investigations after the initial diagnostic surgical intervention will involve a similar work-up as for high risk (>2 cm) appendiceal endocrine tumours. Because GCC bear a higher risk of distant metastases, a chest CT scan is added to the work-up strategy, in addition to a CT scan of abdomen and pelvis or alternatively MRI of the abdomen and pelvis together with somatostatin receptor scintigraphy (SPECT or PET). Lifelong screening for synchronous or metachronous malignancies is recommended. In contrast to appendiceal endocrine tumours CgA determination is not recommended. CEA, CA-19-9 and CA-125 are suggested as tumour markers.

Histopathology

Goblet cell tumours are characterized by a predominant submucosal growth, widespread infiltration of the periappendiceal fat in all cases and extensive perineural invasion. They usually lack the formation of a well-defined tumour mass. The mucosa is characteristically spared. Tumours are composed of small, rounded nests of signet ring-like cells resembling intestinal goblet cells. The cells stain strongly positive for mucicarmine, periodic acid-Schiff, periodic acid-Schiff diastase, alcian blue, cytokeratin, and carcinoembryonic antigen. A proportion of cells are positive with chromogranin and

synaptophysin antibodies. Electron microscopy demonstrates the presence of mucinous vacuoles of varying sizes and occasional membrane-bound neuroendocrine granules. Increased expression of cell proliferation markers and cell cycle markers was observed [31]. GCC are not well represented in studies that have analysed the prognostic value of a number of molecular or pathological factors such as mitotic activity, Ki-67, overexpression of p21 and reduced staining of E-cadherin p21 in gastroenteropancreatic neuroendocrine tumours [40–42]. Thus, no recommendation is available yet.

Minimal Consensus Statement on Histopathology

A complete pathological examination report requires ancillary immunohistochemical tests such as CgA, synaptophysin, and PAS-AB to differentiate other tumour entities. SSR2 or other IHC markers for tumour cell subtyping or malignant behaviour like β -catenin, catestatin A, E-cadherin, P53 or P21 are not required, because their prognostic value is not validated in GCC. Mitotic index and Ki-67 should be assessed following the consensus recommendations, but their correlation with prognosis is unclear in GCC [43].

Surgical Therapy

Right hemicolectomy, usually to be performed after initial appendectomy, is the standard surgical intervention for the majority of GCC, since metastatic risk is high [13, 34]. Right hemicolectomy is recommended to take place within 3 months of the appendectomy, in which case the same surgical strategy applies as for colonic-rectal tumours. Some authors have shown that small (<1 cm) localized tumours, without serosal, mesoappendiceal or caecal invasion, and with low proliferative index, can be better served with appendectomy alone [17, 33]. In these low-risk tumours, metastases rarely develop. Morbidity of right hemicolectomy is not negligible, and can be as high as 40% in the elderly. In female patients with GCC of the appendix, regardless of age, bilateral salpingo-oophorectomy is advocated. Cytoreductive surgery with adjuvant intraperitoneal chemotherapy may offer prolonged survival in cases with advanced peritoneal dissemination [32, 44]. Single-institution experience demonstrates that some patients with peritoneal carcinomatosis may benefit from vast resection, including multiple peritonectomies (Sugarbaker procedures) and intraperitoneal chemotherapy. Treatment of liver metastases might follow the standard procedures recommended in the guidelines for intestinal neuroen-

doctrine carcinomas, but experience is scarce, since this clinical setting seems to be extremely rare. Thus, there are no data to address the question as to whether goblet cell liver metastases should be treated like colorectal cancer.

Minimal Consensus Statement on Surgical Therapy

Hemicolectomy is considered the standard surgical treatment of GCC with additional bilateral salpingo-oophorectomy in female patients. Selection of a more conservative surgery, such as appendectomy, should be carefully individualized in cases without any risk factor for locoregional spread or metastases or in fragile patients. Treatment of liver metastases might follow standard procedures for neuroendocrine tumours.

Medical Therapy and Follow-Up

In cases with obvious spread of the disease, 5-FU-based chemotherapy regimens commonly used for colorectal cancer are advised [32]. Adjuvant therapy with 5-FU and leucovorin is not effective [45]. A case record of a very prolonged complete remission in a patient with disseminated disease has been reported with the Folfox IV regimen [46]. There is no experience with somatostatin analogues, interferon or PRRT because the biology and the pathomolecular features of GCC do not support their use. PRRT could be an option in somatostatin receptor-positive metastatic patients, but is still investigational.

Minimal Consensus Statement on Surgical Therapy and Follow-Up

In spite of the scarcity of data, based on clinical experience and anecdotal reports, it is recommended that patients with advanced GCC are treated with chemotherapy regimen used in colorectal adenocarcinoma. The scheduled follow-up for patients after curative surgical treatment should include clinical, biochemical and imaging control every 3–6 months, then yearly, mimicking the guidelines for colorectal adenocarcinoma. There was no agreement in the duration of the follow-up. Gastrointestinal follow-up is recommended because of the high coincidence (7–48%) of gastrointestinal neoplasm in these patients.

List of Participants

List of Participants of the 'Consensus Conference on the ENETS Guidelines for the Diagnosis and Treatment of Neuroendocrine Gastrointestinal Tumors, Part 2: Midgut and Hindgut Tumors' Held in Frascati (Rome, Italy), November 1–4, 2006

Hakan Ahlman, Institute for Surgical Sciences, Department of Surgery, Sahlgrenska sjukhuset, SE-41345 Gothenburg (Sweden); Rudolf Arnold, Wittelsbacherstr. 6, DE-80469 Munich (Germany); Christoph Auernhammer, Medizinische Klinik II, Grosshadern Klinikum der Ludwig-Maximilians-Universität München, Marchioninistr. 15, DE-81377 Munich (Germany); Martyn Caplin, Royal Free Hospital London, Centre for Gastroenterology, London NW3 2QG (UK); Gianfranco Delle Fave, Ospedale S. Andrea, Via di Grottarossa 1035, IT-00189 Rome (Italy); Barbro Eriksson, Medical Department, Endocrine Unit, University Hospital, SE-75185 Uppsala (Sweden); Diego Ferone, Departments of Internal Medicine and Endocrinological and Metabolic Sciences, University of Genoa, IT-16132 Genoa (Italy); Peter Goretzki, Städtisches Klinikum Neuss, Lukaskrankenhaus, Chirurgische Klinik I, Preussenstr. 84, DE-41456 Neuss (Germany); Rudolf Hyrdel, University Hospital Martin, II. Internal Medical Department, Kollarova 2 (Street), SK-03659 Martin (Slovakia); Robert Jensen, National Institutes of Health, Cell Biology Section, Building 10, Room 9C-193, Bethesda, Md. (USA); Gregory Kaltsas, G. Genimatas Hospital, Mesogion Ave., GR-10443 Athens (Greece); Fahrettin Keleştimur, Erciyes University Medical School, Department of Endocrinology and Metabolism, TR-38039 Kayseri (Turkey); Reza Kianmanesh, UFR Bichat-Beaujon-Louis Mourier, Service de Chirurgie Digestive, Hôpital Louis-Mourier, 178, rue des Renouillers, FR-92700 Colombes (France); Günter Klöppel, Institut für Allgemeine Pathologie und Pathologische Anatomie, Universität Kiel, Michaelisstr. 11, DE-24105 Kiel (Germany); Paul Komminoth, Institute for Pathology, Kantonsspital, CH-5404, Baden (Switzerland); Meike Körner, Institute of Pathology, University of Bern, Murtenstr. 31, Bern (Switzerland); Beata Kos-Kudła, Slaska Akademia Medyczna, Klinika Endokrynologii, ul. 3 Maja 13/15, PL-41800 Zabrze (Poland); Eric Krenning, Erasmus MC, Dr. Molewaterplein 40, NL-3015 GD Rotterdam (The Netherlands); Larry Kvols, H. Lee Moffitt Cancer Center/University of South Florida, Magnolia Drive 12902, Tampa, FL 33612 (USA); Dik Kwেকেboom, Department of Nuclear Medicine, Erasmus University Medical Center, Dr. Molewaterplein 40, NL-3015 GD Rotterdam (The Netherlands); José Manuel Lopes, IPATIMUP, Rua Dr. Roberto Frias SLN, PT-4200, Porto (Portugal); Riccardo Manfredi, Istituto di Radiologia, Policlinico GB Rossi, Piazzale LA Scuro, IT-37134 Ve-

rona (Italy); Anne Marie McNicol, Division of Cancer Sciences and Molecular Pathology, Pathology Department, Royal Infirmary, Castle Street, Glasgow G4 0SF (UK); Bruno Niederle, Universität Wien, Abteilung Chirurgie, Allgemeines Krankenhaus Wien, Währinger Gürtel 18–20, Ebene 3L, AT-1090 Vienna (Austria); Ola Nilsson, Department of Pathology, Sahlgrenska sjukhuset, SE-41345 Gothenburg (Sweden); George Nikou, 68, Plataion Street, GR-15235 Vrilissia/Athens (Greece); Kjell Öberg, Department of Internal Medicine, Endocrine Unit, University Hospital, SE-75185 Uppsala (Sweden); Juan O'Connor, Instituto Alexander Fleming, Crámer 1180, C1426ANZ, Buenos Aires (Argentina); Dermot O'Toole, Service de Gastroentérologie, Centre Hospitalier Universitaire d'Angers, FR-49000 Angers (France); Marianne Pavel, Charité Universitätsmedizin, Department of Internal Medicine, Division of Hepatology and Gastroenterology, Campus Virchow Klinikum, Augustenburger Platz 1, DE-13353 Berlin (Germany); Aurel Perren, Universitätsspital Zürich, Departement Pathologie, Histologielabor PATH F1, Schmelzbergstr. 12, CH-8091 Zürich (Switzerland); John Ramage, Department of Gastroenterology, North Hampshire Hospital, Aldermaston Rd, Basingstoke RG249NA, Hants (UK); Jens Ricke, Otto-von-Guericke-Universität Magdeburg, Klinik für Radiologie und Nuklearmedizin, Leipziger Str. 44, DE-29120 Magdeburg, (Germany); Guido Rindi, Dipartimento di Patologia e Medicina di Laboratorio, Sezione di Anatomia Patologica, Università degli Studi, via A. Gramsci, 14, IT-43100 Parma (Italy); Philippe Ruszniewski, Service de Gastroentérologie, Hôpital Beaujon, 100, Boulevard Général Leclerc, FR-92110 Clichy (France); Aldo Scarpa, Department of Pathology, University of Verona, Strada Le Grazie, 8, IT-37134 Verona (Italy); Jean-Yves Scoazec, Anatomie Pathologique, Hôpital Edouard-Herriot, Bâtiment 10, 3, place d'Arsonval, FR-69437 Lyon, Cedex 03 (France); Maria Isabel Sevilla Garcia, Hospital Virgen de la Victoria, C/Colonía Santa Ines s/n, ES-29010 Malaga (Spain); Thomas Steinmüller, DRK Kliniken Westend, Spandauer Damm 130, DE-14050 Berlin, (Germany); Babs Taal, Netherlands Cancer Centre, Plesmanlaan 121, NL-1066 CX Amsterdam (The Netherlands); Marie-Pierre Vullierme, Service de Gastroentérologie, Hôpital Beaujon, 100, Boulevard Général Leclerc, FR-92110 Clichy (France); Bertram Wiedenmann, Charité Universitätsmedizin, Department of Internal Medicine, Division of Hepatology and Gastroenterology, Campus Virchow Klinikum, Augustenburger Platz 1, DE-13353 Berlin (Germany); Stefan Wildi, University Hospital of Zürich, Department of Visceral and Transplantation Surgery, CH-8091 Zürich (Switzerland); James C. Yao, The University of Texas M.D. Anderson Cancer Center, 1515 Holcombe Boulevard, Houston, TX 77030 (USA).

References

- 1 Solcia E, Klöppel G, Sobin LH: Histological Typing of Endocrine Tumours, ed 2. WHO International Histological Classification of Tumours. Berlin, Springer, 2000.
- 2 Caplin ME, Buscombe JR, Hilson AJ, Jones AL, Watkinson AF, Burroughs AK: Carcinoid tumour. *Lancet* 1998;352:799–805.
- 3 Godwin JD 2nd: Carcinoid tumors. An analysis of 2,837 cases. *Cancer* 1975;36:560–569.
- 4 Hemminki K, Li X: Incidence trends and risk factors of carcinoid tumors: a nationwide epidemiologic study from Sweden. *Cancer* 2001;92:2204–2210.
- 5 Kulke MH, Mayer RJ: Carcinoid tumors. *N Engl J Med* 1999;340:858–868.
- 6 Maggard MA, O'Connell JB, Ko CY: Updated population-based review of carcinoid tumors. *Ann Surg* 2004;240:117–122.
- 7 Modlin IM, Lye KD, Kidd M: A five-decade analysis of 13,715 carcinoid tumors. *Cancer* 2003;97:934–959.

- 8 Vinik AI, McLeod MK, Fig LM, Shapiro B, Lloyd RV, Cho K: Clinical features, diagnosis, and localization of carcinoid tumors and their management. *Gastroenterol Clin North Am* 1989;18:865–896.
- 9 McGory ML, Maggard MA, Kang H, O'Connell JB, Ko CY: Malignancies of the appendix: beyond case series reports. *Dis Colon Rectum* 2005;48:2264–2271.
- 10 Moertel CG, Dockerty MB, Judd ES: Carcinoid tumors of the vermiform appendix. *Cancer* 1968;21:270–278.
- 11 O'Donnell ME, Carson J, Garstin WI: Surgical treatment of malignant carcinoid tumours of the appendix. *Int J Clin Pract* 2007;61:431–437.
- 12 Sandor A, Modlin IM: A retrospective analysis of 1,570 appendiceal carcinoids. *Am J Gastroenterol* 1998;93:422–428.
- 13 Goede AC, Caplin ME, Winslet MC: Carcinoid tumour of the appendix. *Br J Surg* 2003;90:1317–1322.
- 14 Iwuagwu OC, Jameel JK, Drew PJ, Hartley JE, Monson JR: Primary carcinoma of the appendix – Hull series. *Dig Surg* 2005;22:163–167.
- 15 Moertel CG, Weiland LH, Nagorney DM, Dockerty MB: Carcinoid tumor of the appendix: treatment and prognosis. *N Engl J Med* 1987;317:1699–1701.
- 16 Stinner B, Rothmund M: Neuroendocrine tumours (carcinoids) of the appendix. *Best Pract Res Clin Gastroenterol* 2005;19:729–738.
- 17 Deans GT, Spence RA: Neoplastic lesions of the appendix. *Br J Surg* 1995;82:299–306.
- 18 McCusker ME, Cote TR, Clegg LX, Sobin LH: Primary malignant neoplasms of the appendix: a population-based study from the surveillance, epidemiology and end-results program, 1973–1998. *Cancer* 2002;94:3307–3312.
- 19 Moertel CL, Weiland LH, Telander RL: Carcinoid tumor of the appendix in the first two decades of life. *J Pediatr Surg* 1990;25:1073–1075.
- 20 Thirlby RC, Kasper CS, Jones RC: Metastatic carcinoid tumor of the appendix. Report of a case and review of the literature. *Dis Colon Rectum* 1984;27:42–46.
- 21 Safioleas MC, Moulakakis KG, Kontzoglou K, Stamoulis J, Nikou GC, Toubanakis C, Lygidakis NJ: Carcinoid tumors of the appendix. Prognostic factors and evaluation of indications for right hemicolectomy. *Hepatogastroenterology* 2005;52:123–127.
- 22 Syracuse DC, Perzin KH, Price JB, Wiedel PD, Mesa-Tejada R: Carcinoid tumors of the appendix. Mesoappendiceal extension and nodal metastases. *Ann Surg* 1979;190:58–63.
- 23 Dunn JP: Carcinoid tumours of the appendix: 21 cases, with a review of the literature. *NZ Med J* 1982;95:73–76.
- 24 Prommegger R, Obrist P, Ensinger C, Schwelberger HG, Wolf C, Fischer-Colbrie R, Mikuz G, Bodner E: Secretoneurin in carcinoids of the appendix-immunohistochemical comparison with chromogranins A, B and secretogranin II. *Anticancer Res* 1998;18:3999–4002.
- 25 Rossi G, Valli R, Bertolini F, Sighinolfi P, Losi L, Cavazza A, Rivasi F, Luppi G: Does mesoappendix infiltration predict a worse prognosis in incidental neuroendocrine tumors of the appendix? A clinicopathologic and immunohistochemical study of 15 cases. *Am J Clin Pathol* 2003;120:706–711.
- 26 MacGillivray DC, Heaton RB, Rushin JM, Cruess DF: Distant metastasis from a carcinoid tumor of the appendix less than one centimeter in size. *Surgery* 1992;111:466–471.
- 27 Thompson GB, van Heerden JA, Martin JK Jr, Schutt AJ, Ilstrup DM, Carney JA: Carcinoid tumors of the gastrointestinal tract: presentation, management, and prognosis. *Surgery* 1985;98:1054–1063.
- 28 Pickhardt PJ, Levy AD, Rohrmann CA Jr, Kende AI: Primary neoplasms of the appendix: radiologic spectrum of disease with pathologic correlation. *Radiographics* 2003;23:645–662.
- 29 Dall'Igna P, Ferrari A, Luzzatto C, Bisogno G, Casanova M, Alaggio R, Terenziani M, Cecchetto G: Carcinoid tumor of the appendix in childhood: the experience of two Italian institutions. *J Pediatr Gastroenterol Nutr* 2005;40:216–219.
- 30 Bamboat ZM, Berger DL: Is right hemicolectomy for 2.0-cm appendiceal carcinoids justified? *Arch Surg* 2006;141:349–352.
- 31 Kanthan R, Saxena A, Kanthan SC: Goblet cell carcinoids of the appendix: immunophenotype and ultrastructural study. *Arch Pathol Lab Med* 2001;125:386–390.
- 32 Pahlavan PS, Kanthan R: Goblet cell carcinoid of the appendix. *World J Surg Oncol* 2005;3:36.
- 33 Bucher P, Gervaz P, Ris F, Oulhaci W, Egger JF, Morel P: Surgical treatment of appendiceal adenocarcinoid (goblet cell carcinoid). *World J Surg* 2005;29:1436–1439.
- 34 Butler JA, Houshiar A, Lin F, Wilson SE: Goblet cell carcinoid of the appendix. *Am J Surg* 1994;168:685–687.
- 35 Bader TR, Semelka RC, Chiu VC, Armao DM, Woosley JT: MRI of carcinoid tumors: spectrum of appearances in the gastrointestinal tract and liver. *J Magn Reson Imaging* 2001;14:261–269.
- 36 Chiti A, Fanti S, Savelli G, Romeo A, Bellanova B, Rodari M, van Graafeiland BJ, Monetti N, Bombardieri E: Comparison of somatostatin receptor imaging, computed tomography and ultrasound in the clinical management of neuroendocrine gastroenteropancreatic tumours. *Eur J Nucl Med* 1998;25:1396–1403.
- 37 Dromain C, de Baere T, Lumbroso J, Caillet H, Laplanche A, Boige V, Ducreux M, Duvillard P, Elias D, Schlumberger M, Sigal R, Baudin E: Detection of liver metastases from endocrine tumors: a prospective comparison of somatostatin receptor scintigraphy, computed tomography, and magnetic resonance imaging. *J Clin Oncol* 2005;23:70–78.
- 38 Gabriel M, Decristoforo C, Kendler D, Dobrozemsky G, Heute D, Uprimny C, Kovacs P, Von Guggenberg E, Bale R, Virgolini IJ: ⁶⁸GA-DOTA-Tyr³-octreotide PET in neuroendocrine tumors: comparison with somatostatin receptor scintigraphy and ct. *J Nucl Med* 2007;48:508–518.
- 39 Bucher P, Gervaz P, Ris F, Oulhaci W, Inan I, Morel P: Laparoscopic versus open resection for appendix carcinoid. *Surg Endosc* 2006;20:967–970.
- 40 Kawahara M, Kammori M, Kanauchi H, Noguchi C, Kuramoto S, Kaminishi M, Endo H, Takubo K: Immunohistochemical prognostic indicators of gastrointestinal carcinoid tumours. *Eur J Surg Oncol* 2002;28:140–146.
- 41 Sokmensuer C, Gedikoglu G, Uzunalimoglu B: Importance of proliferation markers in gastrointestinal carcinoid tumors: a clinicopathologic study. *Hepatogastroenterology* 2001;48:720–723.
- 42 Van Eeden S, Quaedvlieg PF, Taal BG, Offerhaus GJ, Lamers CB, Van Velthuysen ML: Classification of low-grade neuroendocrine tumors of midgut and unknown origin. *Hum Pathol* 2002;33:1126–1132.
- 43 Rindi G, Kloppel G, Alhman H, Caplin M, Couvelard A, de Herder WW, Eriksson B, Falchetti A, Falconi M, Komminoth P, Korner M, Lopes JM, McNicol AM, Nilsson O, Perren A, Scarpa A, Scoazec JY, Wiedenmann B: TNM staging of foregut (neuro)endocrine tumors: a consensus proposal including a grading system. *Virchows Arch* 2006;449:395–401.
- 44 Mahteme H, Sugarbaker PH: Treatment of peritoneal carcinomatosis from adenocarcinoid of appendiceal origin. *Br J Surg* 2004;91:1168–1173.
- 45 Pham TH, Wolff B, Abraham SC, Drelichman E: Surgical and chemotherapy treatment outcomes of goblet cell carcinoid: a tertiary cancer center experience. *Ann Surg Oncol* 2006;13:370–376.
- 46 Garin L, Corbinais S, Boucher E, Blanchot J, Le Guilcher P, Raoul JL: Adenocarcinoid of the appendix vermiformis: complete and persistent remission after chemotherapy (Folfox) of a metastatic case. *Dig Dis Sci* 2002;47:2760–2762.
- 47 Rindi G, Kloppel G, Couvelard A, Komminoth P, Korner M, Lopes JM, McNicol AM, Nilsson O, Perren A, Scarpa A, Scoazec JY, Wiedenmann B: TNM staging of midgut and hindgut (neuro)endocrine tumors: a consensus proposal including a grading system. *Virchows Arch* 2007;451:757–762.