

ENETS Consensus Guidelines for the Management of Patients with Gastroduodenal Neoplasms

Gianfranco Delle Fave^a Dik J. Kwekkeboom^b Erik Van Cutsem^c Guido Rindi^d
Beata Kos-Kudla^e Ulrich Knigge^f Hironobu Sasano^g Paola Tomassetti^h
Ramon Salazarⁱ Philippe Ruszniewski^j
all other Barcelona Consensus Conference participants¹

^aDepartment of Digestive and Liver Disease, Ospedale Sant'Andrea, Rome, Italy; ^bDepartment of Oncology, Royal Free University UFR Bichat-Beaujon-Louis Mourier, Colombes, France; ^cDigestive Oncology, University Hospital Gasthuisberg/Leuven, Leuven, Belgium; ^dInstitute of Pathology, Catholic University – Policlinic A. Gemelli, Rome, Italy; ^eDepartment of Endocrinology, Medical University of Silesia, Katowice, Poland; ^fDepartment of Surgery, Rigshospitalet, Copenhagen University Hospital, Copenhagen, Denmark; ^gDepartment of Pathology, Tohoku University Graduate School of Medicine, Sendai, Japan; ^hDepartment of Internal Medicine and Gastroenterology, St. Orsola Hospital, University of Bologna, Bologna, Italy; ⁱInstitut Català d'Oncologia (IDIBELL), Barcelona, Spain; ^jDepartment of Gastroenterology, Beaujon Hospital, Clichy, France

Introduction

Gastric neuroendocrine neoplasms (g-NENs) [1] are increasingly recognized due to expanding indications of upper gastrointestinal (UGI) endoscopy. Often silent and benign, g-NENs may, however, be aggressive when sporadic and may sometimes mimic the course of gastric adenocarcinoma.

Duodenal neuroendocrine tumors (d-NENs) [2] may or may not be associated with a functional clinical syndrome. The term d-NEN includes all duodenal tumors with neuroendocrine (NE) features as determined by histological/immunohistochemical methods including positivity for NE cytosolic markers (neuron-specific enolase (NSE), PGP 9.5) or secretory vesicle proteins (chromogranin A (CgA), synaptophysin) and also frequently the presence of specific gastrointestinal (GI) hormones [3–8]. The term d-NEN in this paper refers to tumors includ-

ed in different studies classified as: duodenal carcinoid; duodenal gastroenteropancreatic (GEP) tumor; duodenal pancreatic neuroendocrine tumor (p-NET); duodenal gastrinoma; duodenal somatostatinoma; gangliocytic paraganglioma; ampullary carcinoid or somatostatinoma; argentaffin carcinoid-producing serotonin of the duodenum; psammomatous somatostatinoma; duodenal NE carcinoma, poorly differentiated and small-cell NE carcinoma of the duodenum [6]. The clinical and management aspect of duodenal gastrinomas are included in the 'Endocrine Tumors of the Pancreas – Gastrinoma' section and duodenal gastrinomas will only be considered in this section in comparison with the other d-NENs.

¹ See list at the end of the paper.

Table 1. Summary of the main characteristics of g-NENs

	Type 1	Type 2	Type 3
Proportion among g-NENs, %	70–80	5–6	14–25
Tumor characteristics	often small (<1–2 cm), multiple in 65% of cases, polypoid in 78% of cases	often small (<1–2 cm) and multiple, polypoid	unique, often large (>2 cm) polypoid and ulcerated
Associated conditions	chronic atrophic gastritis	gastrinoma/MEN1	none
Pathology	often NET G1	NET G1-G2	NET G3
Serum gastrin levels	↑	↑	normal
Gastric pH	↑↑	↓↓	normal
Metastases, %	2–5	10–30	50–100
Tumor-related deaths, %	0	<10	25–30

Epidemiology and Clinicopathological Features

Gastric Neuroendocrine Tumors

Gastric carcinoids (g-NENs) are reported, on the basis of a prospective study, to represent up to 23% of all digestive NE neoplasms [9], with a yearly age-adjusted incidence of around 0.2 per population of 100,000. g-NENs may be divided into three types: types 1 and 2 are ECLomas, due to chronic hypergastrinemia, while type 3 NENs are rare and sporadic, as they are not a consequence of any gastric background pathology; they are mostly located in the fundus/gastric corpus, but antral localization is possible. Type 1 gastric carcinoids arise in achlorhydria secondary to (autoimmune) atrophic fundic gastritis, while type 2 develop in response to hypergastrinemia resulting from neoplastic secretion from gastrinomas (Zollinger-Ellison syndrome (ZES)), mostly in patients presenting with multiple endocrine neoplasia type 1 [10–24]. Table 1 summarizes the main characteristics of g-NENs.

Type 1 tumors represent 75–80% of all g-NENs and, as they involve only patients with atrophic body gastritis (2.4% of patients with atrophy at time of first diagnosis) [25], occur mostly in women and are rarely responsible for symptoms [26]. In fact, they usually are non-functioning tumors, typically found during UGI endoscopy performed for dyspepsia or for macrocytic or iron deficiency anemia [13, 18, 21, 23, 27]. This condition is associated to slow gastric emptying (explaining dyspepsia) and progressive reduction of acid output, thus impairing iron and vitamin B₁₂ absorption [27]. They present frequently as polyps in the gastric fundus, but can be also detected only at biopsies (microcarcinoids, 22.2%). Lesions are multiple in about 65% of cases, with a median diameter

of 5 mm [28]. They are usually benign and well differentiated (NET G1) [29], however, rare cases of metastatic spread and bad prognosis have been described in the literature [30]. Type 2 tumors (ECLomas in the course of ZES) are almost exclusively seen in multiple endocrine neoplasia type 1 (MEN-1) patients [12, 31–33], occurring in 23–29% of such cases (as compared with 1–3% in sporadic gastrinomas) [34, 35]. They appear as small (diameter 1–2 cm) polyps and may involve the entire fundic mucosa. They are generally asymptomatic. Type 3 tumors are usually solitary and mostly belong to WHO group 3 (NET G3), with high Ki67, big diameter with infiltrative growth; they occur mostly in men over 50 years of age [10–12, 26, 36, 37]. They may be discovered incidentally, but are often responsible for pain, weight loss, and iron deficiency anemia. Atypical carcinoid syndrome due to histamine production is extremely rare.

Minimal Consensus Statements on Epidemiology and Clinicopathological Features

The yearly age-adjusted incidence of gastric type 1 and 2 endocrine tumors is approximately 0.2 per population of 100,000; however, these tumors are probably underdiagnosed, and g-NENs are reported to represent up to 23% of all digestive NE tumors. Type 1 tumors are the most common neuroendocrine tumors of the stomach (70–85%) and they are usually benign (NET G1). Type 2 tumors, however, are much rarer; however, up to 35% of cases are metastatic at presentation. Type 1 gastric carcinoids occur more frequently in women and 70–80% of tumors are classically diagnosed in the 5th and 7th decades, although with the more extensive use of endoscopy the age limit may be younger particularly in those patients with multiple autoimmune diseases. Type 1 have almost universally good prognosis with rare tumor-related death at follow-up. Among type 2 gastric carcinoids, death due to metastatic g-NENs is exceptional.

Small gastric carcinoids are usually asymptomatic. Although <1% of patients in literature are described to complain 'atypical carcinoid syndrome', clinical experience shows that type 1 are more frequently associated to dyspepsia and anemia, related to atrophic body gastritis.

Duodenal Neuroendocrine Tumors

d-NENs comprise 1.8% of all NE tumors in the ERG Group (1950–1969), 2–3% of the Third NCS Survey (1969–1971), 1.9% of the early SEER Registry (1973–1991), 3.8% of the Late SEER Registry (1992–1999), and 2.8% of the PAN-SEER Registry (1973–1999) [5, 38, 39]. Primary duodenal neoplasms occur in 0.03–0.05% of all autopsies [40]. d-NENs comprise 1–3% of all primary duodenal tumors [4].

In some studies, d-NENs were classified generally into five different tumor types [3]. These included duodenal gastrinomas, somatostatinomas, non-functional d-NENs which were not associated with a clinical syndrome but often demonstrated hormones with immunohistochemistry including serotonin and calcitonin, duodenal gangliocytic paragangliomas, and high-grade poorly differentiated NECs [3, 6]. Many studies also differentiated ampulla of Vater or periampullary NENs because numerous studies demonstrated they differed from other d-NENs clinically, histologically and in their growth behaviors [41–46]. Ampullary NENs are frequently associated with von Recklinghausen's disease and often show somatostatin immunoreactivity, but almost never produce the clinical features of the somatostatinoma syndrome [6, 8, 41, 44, 47–51].

In older studies reporting on the five types of d-NENs, duodenal gastrinomas were the most frequent (mean 48.3% of all d-NENs, range 27–58%, 9 series) [6, 8, 41, 42, 52–58], followed by somatostatinomas (mean 43 ± 6%, range 23–75%, 9 series), non-functional serotonin-containing tumors (mean 27.6 ± 7.2%, 6 series), non-functional calcitonin-containing NETs (mean 9 ± 2.5%, 4 series) [6], and finally rare gangliocytic paragangliomas or NE carcinomas.

More than 90% of all d-NENs arise in the first and second part of the duodenum [6, 52, 53, 55, 57]. This has been well studied for duodenal gastrinomas [7, 8, 41, 52, 53, 55, 56, 58, 59] where 58% arise in D1, 33% arise in D2, 5% in D3 and 4% in D4 [60–64]. Approximately 20% (mean 18 ± 5%, 6 series) of d-NENs occur in the periampullary region [6].

d-NENs are generally small with a mean size of 1.2–1.5 cm in 7 series [6] and >75% are <2 cm in diameter [6, 7, 41, 42, 55, 56, 59]. d-NENs are usually limited to the sub-

mucosa or mucosa; however, they are associated with regional lymph node metastases in 40–60% of cases [3, 6, 61, 65–67]. Liver metastases generally occur in <10% of all patients with d-NENs (mean 9 ± 6%, 5 series) [6].

d-NENs are generally single lesions with multiple tumors detected in only 9 ± 3% (5 series) [6, 42, 52, 55–57]. Multiple tumors should lead to a suspicion of MEN-1. MEN-1 occurs in 6 ± 2.5% of all patients with d-NENs (mean, 8 series) [6, 8, 41, 52–54, 56–58]. However, MEN-1 occurs in 20–30% of all patients with d-NENs with ZES [65, 67–69].

Duodenal gangliocytic paragangliomas generally occur in the periampullary region [3, 43, 57, 71, 72]. These tumors may be large and invade the muscularis propria, but generally pursue a benign course [6, 42, 46, 73].

A WHO classification has recently been proposed for duodenal/jejunal NETs that will allow a better comparison to NETs in other locations [3]. This classification is summarized in the specific section below with a few other important points covered in the general clinicopathological section above.

The mean age of presentation is in the 6th decade (range 15–91 years) and there is a slight male predominance (65 ± 5%, 9 series) [6]. Because 90% of d-NENs are not associated with a functional clinical syndrome, either symptoms due to the tumor itself or the discovery of the tumor by chance (usually at UGI endoscopy) lead to the diagnosis. The most common presenting symptoms are pain (37 ± 8%, range 9–64%, 6 series), jaundice (18 ± 4%, range 7–32%), nausea/vomiting (4 ± 8%), bleeding (21 ± 3%), anemia (21 ± 3%, range 1–28), diarrhea (4%) and duodenal obstruction (1%) [7, 41, 55, 56, 74, 75]. Symptoms due to ZES are present in 10 ± 3% of all patients with d-NENs followed by carcinoid syndrome in 4 ± 2%, and rarely due to Cushing's syndrome, acromegaly due to a GRF-secreting tumor, somatostatinoma syndrome, insulinoma, glucagonoma or due to the development of polycythemia rubra vera [6, 47, 49, 50, 75–77]. An increasing percentage of d-NENs are being diagnosed in asymptomatic patients during an UGI endoscopy (up to 33%). The most common non-specific symptom that led to the endoscopy was dyspepsia [41]. Periampullary NETs more frequently present with jaundice (50–60 vs. 7–15%) and also more frequently cause pain, nausea, diarrhea or vomiting [41, 42, 44, 46]. Periampullary NETs are more frequently associated with von Recklinghausen's disease (18%) and the presence of somatostatin immunoreactivity (25–100%); however, a clinical somatostatinoma syndrome is very rare with these tumors [6, 8, 41, 42, 44, 78].

Minimal Consensus Statement on Epidemiology and Clinicopathological Features

General

d-NENs comprise 1.8% of all NE neoplasms in the ERG Group (1950–1969), 2–3% of the Third NCS Survey (1969–1971), 1.9% of the early SEER Registry (1973–1991), 3.8% of the Late SEER Registry (1992–1999), and 2.8% of the PAN-SEER Registry (1973–1999) [5, 38, 39]. Primary duodenal neoplasms occur in 0.03–0.05% of all autopsies [40]. d-NENs comprise 1–3% of all primary duodenal tumors [4].

Although >95% of d-NENs synthesize GI peptides/amines, 90% are not associated with a functional syndrome. In the 10% that cause a functional syndrome the relative frequency is: ZES (10%) > carcinoid syndrome (4%) > other (<1%). d-NENs occur in greatest frequency in the proximal duodenum and 40–60% have lymph node metastases. Twenty percent of d-NENs occur in the periampullary region and these differ from other d-NENs in their biological behavior and also with respect to clinical, histological and immunohistochemical features.

Specific

Classification

- (1) NET G1 (50–75%). (Percentage of all d-NENs.) Benign: non-functioning, confined to mucosa-submucosa, non-angioinvasive, ≤1 cm in size.
 - Gastrin-producing tumor (upper part of the duodenum)
 - Serotonin (5-HT)-producing tumor
 - Gangliocytic paraganglioma (any size and extension, periampullary) Benign or low-grade malignant (uncertain malignant potential): confined to mucosa-submucosa, with or without angioinvasion, or >1 cm in size
 - Functioning gastrin-producing tumor (gastrinoma), sporadic or MEN-associated
 - Non-functioning somatostatin-producing tumor (ampullary region) with or without
 - Neurofibromatosis type 1 non-functioning serotonin-producing tumor
- (2) NET G2 (25–50%). Low-grade malignant: invasion of the muscularis propria and beyond or metastases
 - Functioning gastrin-producing carcinoma (gastrinoma), sporadic or MEN-associated
 - Non-functioning somatostatin-producing carcinoma (ampullary region) with or without neurofibromatosis type 1
 - Non-functioning or functioning carcinoma (with carcinoid syndrome)
 - Malignant gangliocytic paraganglioma
- (3) NEC (<1–3%)
 - High-grade malignant

Prognosis and Survival

Gastric Neuroendocrine Tumors

Prognosis of g-NENs is different according to carcinoid type. Type 1 tumors, being usually well differentiated and with low Ki67 (NET G1), generally have an ex-

cellent prognosis. Patients managed by endoscopic follow-up and lesions resection have shown 100% survival, with lesions confined to submucosa and no metastases during observation. However, this is a recurring disease, showing a median recurrence-free survival of 24 months and with 3% of cases developing NEC [10]. Type 2 g-NENs have a metastatic rate of 10–30%, with a mortality <10%; metastases involve more frequently the liver and abdominal lymph nodes. Type 3 g-NENs have a mortality of 25–30%, and a metastatic rate of 50–100%; extra-abdominal secondary lesions can be present [11, 19, 20].

Minimal Consensus Statements on Prognosis and Survival

Type 1 g-NENs represent a recurring disease; patients managed by endoscopic follow-up and lesions resection (when found) have a recurrence-free survival of about 24 months, and 100% survival. Type 2 and 3 g-NEN lesions mostly metastasize, as all digestive NETs, to the liver and proximal lymph nodes; however, especially for type 3, extra-abdominal metastases are possible. For type 1, gastric carcinoids are generally confined to submucosa; metastases and poorly differentiated tumors are rare, accounting for the Italian experience of about 3%. However, if patients are managed by strict endoscopic follow-up, these aggressive lesions can be detected early and radically treated by surgery.

Duodenal Neuroendocrine Tumors

For all patients with well-differentiated d-NENs (carcinoid) the 5-year survival rate is 80–85% [59, 74], whereas for patients with well-differentiated duodenal carcinomas or variant duodenal carcinoid it is significantly ($p < 0.01$) less at 72% [59].

For patients with d-NENs associated with ZES the 5-year survival is >90% [61, 66, 67]. d-NENs characteristically metastasize first to proximal lymph nodes and only infrequently (<10%) to the liver or distant sites. The 5-year survival with different tumor extent with d-NENs is thought to be similar to all GI foregut NETs which is 80–95% for local disease, 65–75% with regional involvement only, and 20–40% for the 5–10% of patients with liver or distant disease [39, 58, 74]. Invasion of the d-NEN into the muscularis mucosa, increased primary tumor size, and increased mitotic activity correlate with the occurrence of metastatic disease or aggressive growth [7, 41, 42, 56]. Ampullary NETs are reported to share different growth patterns than do non-ampullary d-NENs. Two studies report [41, 44] that there was no relationship between these tumors and the development of metastases with primary tumor size.

Minimal Consensus Statements on Prognosis and Survival

The 5-year survival with different tumor extent with d-NENs is thought to be similar to all GI foregut NENs which is 80–95% for local disease, 65–75% with regional involvement only, and 20–40% for the 5–10% of patients with liver or distant disease [39, 58, 74]. d-NENs characteristically metastasize first to proximal lymph nodes and only infrequently (<10%) to the liver or distant sites. Invasion of the d-NEN into the muscularis mucosa, increased primary tumor size, and increased mitotic activity correlate with the occurrence of metastatic disease or aggressive growth [7, 41, 42, 56]. Ampullary NENs are reported to share different growth patterns than do non-ampullary d-NENs.

Diagnostic Procedures: Imaging, Nuclear Medicine and Laboratory Tests

Gastric Neuroendocrine Tumors

Imaging techniques such as multislice CT scan and MRI are of very limited value for small type 1 and 2 tumors in terms of cost-benefit ratio. In case of small (<1 cm) ECLomas, UGI endoscopy is usually the only recommended imaging procedure: diagnosis is made at UGI and biopsy samples should be taken from the antrum (2 biopsies) and body/fundus (4 biopsies) in addition to biopsies of the largest polyps [79]. Endoscopic ultrasonography (EUS) may help to determine tumor invasion in the depth of the gastric wall and is to be recommended before resection of polyps >1–2 cm in diameter [28]. When there is a risk of metastases, and mainly in cases of sporadic tumors (type 3), an extensive search should be performed. EUS is useful in assessing regional lymph-node involvement and allows histological confirmation by fine-needle aspiration. Transabdominal ultrasonography, and mainly CT scan and MRI, have a high sensitivity/specificity to detect liver metastases. Somatostatin receptor scintigraphy (SRS) is recommended in these patients to search for liver, bone and lymph node metastases. Laboratory tests are of major interest, especially in patients with type 1 or 2 ECLomas. In these patients, basal serum gastrin levels should be determined and are always elevated [17, 28, 80, 81], as well as plasma CgA levels [28, 82]. Further tests should be performed depending on the clinical context. In the majority of the cases (type 1 tumors), no symptoms of ZES are present and UGI endoscopy does not show any lesion related to peptic disease.

The search for autoimmune disease should include anti-parietal cell and anti-intrinsic factor autoantibodies,

present in about 50% of the patients with gastric atrophy [11]; the *Helicobacter pylori* status has to be assessed. Gastrin and CgA rates are not necessarily to be measured during follow-up. Thyroid functional test and thyroperoxidase antibodies should be assessed at diagnosis to better define chronic atrophic gastritis and possible association with autoimmune thyroiditis [28]. In patients with ZES, laboratory tests are limited to CgA and serum gastrin levels measurement [31, 32, 83, 84]. EUS is necessary before endoscopic resection of big polyps, and in patients affected by type 2 g-NENs diagnostic work-up for MEN-1 syndrome has to be followed (CT/MRI useful). In patients with type 3 sporadic tumors, which occur independent of hypergastrinemia, determination of CgA level is useful in patients with well-differentiated tumors.

Minimal Consensus Statements on Diagnostic Procedures

Diagnosis is made at UGI and biopsy samples should be taken from the antrum (2 biopsies) and fundus (4 biopsies) in addition to biopsies of the largest polyps. For type 1 and small type 2 tumors, endoscopy and biopsy usually suffice. For type 1 and type 2 tumors, EUS should be performed in tumors >1–2 cm in size before endoscopic resection. CT scan, MRI, and SRS are not required for type 1, but can be useful in type 2 tumors, according to MEN-1 work-up. The minimal biochemical tests in patients with type 1 and type 2 tumors include serum gastrin and CgA levels. *H. pylori* antibodies, parietal cell antibodies, thyroid functional test and thyroperoxidase antibodies should be assessed at diagnosis to better define chronic atrophic gastritis and possible association with autoimmune thyroiditis. Indication of repeating CgA and gastrin determinations during follow-up is not assessed.

Duodenal Neuroendocrine Neoplasms

Because d-NENs are generally small in size (mean 1.2–1.5 cm) (>75% <2 cm) [6, 7, 41, 42, 52, 53, 55, 56, 58, 59], they are frequently missed (>80%) with conventional imaging studies (multislice CT scan, MRI, ultrasound, angiography) [46, 60, 61, 64, 85–89]. Studies in gastrinomas demonstrate that conventional imaging studies detect ≤15% of gastrinomas <1 cm in diameter, 20–50% 1–3 cm in diameter, and 95% >3 cm in diameter [85, 87, 89].

Although there are no systematic studies with all d-NENs, studies with SRS in duodenal gastrinomas show it is unlikely to be a more sensitive method to localize small duodenal primaries <1 cm. SRS misses 50% of tumors <1 cm in diameter [61, 89–91]. However, SRS will likely prove to be the most sensitive modality for detecting lymph node metastases, which occur in 40–60% of all patients with d-NENs [3, 6, 61, 65–67].

To detect the primary d-NEN, UGI endoscopy with biopsy is the most sensitive modality with endoscopic ultrasound (EUS) used to confirm the diagnosis and locally stage the disease [92–96]. Some d-NENs such as gastrinomas may be primarily submucosal in location and these may be missed on both UGI endoscopy and/or EUS resulting in detection rates as low as 30–60% for duodenal gastrinomas causing ZES, which were diagnosed by hormone assays [97–99].

For full staging of d-NENs, multislice CT scan is generally used [92, 93], although studies with gastrinomas suggest SRS may be more sensitive [89, 91, 100, 101].

In patients with advanced metastatic disease, bone metastases can develop especially in those with diffuse liver metastases. It is important they be sought because in other NETs their detection has been shown to generally change management [101–108]. SRS, bone scan and MRI of the spine best detect them. For what concerns laboratory tests, plasma CgA should be obtained in all patients with d-NENs. An elevated CgA level occurs in 56–100% [41, 86, 109, 110]. Serum gastrin, somatostatin, GRF and cortisol with urinary 5-HIAA or cortisol determinations should be obtained if suggestive symptoms occur or if the d-NEN contains these hormones on immunohistochemistry. Patients with MEN-1 with a d-NEN should have serum somatostatin, gastrin, CgA, prolactin, glucagon, insulin and PTH determinations as well as serum glucose and ionized calcium assessments. Patients with von Recklinghausen's disease should have serum somatostatin, CgA, and calcitonin levels assessed.

Minimal Consensus Statement on Diagnostic Procedures

UGI endoscopy with biopsies is the most sensitive method to detect and diagnose most d-NENs, followed by endoscopic ultrasound to locally stage the disease extent. EUS is also useful before resection in polypoid lesions.

Multislice CT scan or MRI of the abdomen and SRS should be used to fully assess disease extent and detect possible distant metastases. In patients with advanced disease, including especially patients with liver metastases, bone scan, SRS and an MRI of the spine should be performed to seek bone metastases.

For what concerns laboratory tests, plasma CgA should be obtained in all patients with d-NENs. Serum gastrin, somatostatin, GRF and cortisol with urinary 5-HIAA or cortisol determinations should be obtained if suggestive symptoms occur or if the d-NEN contains these hormones on immunohistochemistry. Patients with MEN-1 with a d-NEN should have serum somatostatin, gastrin, CgA, prolactin, glucagon, insulin and PTH determinations as well as serum glucose and ionized calcium assessments. Patients with von Recklinghausen's disease should have serum somatostatin, CgA, and calcitonin levels assessed.

Pathology and Genetics

Gastric Neuroendocrine Neoplasms

Pathological diagnosis is mandatory in all cases and is easily obtained from tumor biopsies performed during UGI (for type 3 g-NENs), or preferably upon examination of a whole tumor (polyp) removed using endoscopic mucosal resection (ECLomas type 1 and 2). In case of multiple polyps, biopsies of fundic non-polypoid mucosa should also be performed in order to establish the diagnosis of associated atrophic gastritis [79]. In this latter condition, polyps may be of various origin and correspond to hyperplastic or inflammatory polyps, adenomas or even early gastric adenocarcinomas, as well as ECLomas. Multiple biopsies of different lesions should thus be performed, especially if macroscopic appearance of one lesion differs from that of the others. Pathological diagnosis of g-NENs is performed using conventional hematoxylin and eosin staining, immunohistochemical staining with CgA and synaptophysin [11, 14, 16, 24, 31]. Determination of mitotic index by counting 10 HPF and calculation of Ki67 index by immunohistochemistry are mandatory [29, 111]. The tumors should be classified according to the WHO in NET or NEC, and G1-G3; the great majority of g-NENs fall within group 1 tumors. Most ECLomas are preceded (or accompanied) by linear or micronodular hyperplasia or dysplasia of ECL cells. This condition is associated with a 26-fold increase in the risk of developing ECLomas in patients with chronic atrophic gastritis [79]. Immunohistochemistry for p53 or SSR2A receptors in type 1 or type 2 tumors is not recommended. Somatic (tumor) DNA testing is not recommended. As outlined above, the presence of ECLomas in a patient with ZES makes the diagnosis of MEN-1 very likely, and in that case germline DNA testing is recommended in the presence of a positive family history of MEN-1 or if multiple tumors are present in the absence of atrophic gastritis in the rare instances when MEN-1 diagnosis has not been done previously. Genetic testing when performed should include mutational screening and sequencing, allowing for analysis of the entire coding gene and splice sites and genetic counseling should be sought prior to testing in all patients. Informed consent is mandatory prior to genetic testing.

In type 3 tumors, proliferative index using Ki67 antibody is frequently elevated [36]. Genetic testing for hereditary tumor syndrome should only be performed in case of suspected or established diagnosis of ZES.

Minimal Consensus Statements on Pathology and Genetics

Histology is always necessary to establish a diagnosis. The minimal ancillary tests to support the histological diagnosis include immunohistochemistry for CgA and synaptophysin. Both the mitotic count in 10 HPF and the Ki67 index (the latter performed using immunohistochemistry, although the techniques and counting standards need to be established) are mandatory in all cases. Ki67 is useful to classify patients according to WHO classification 2010 (G1-G3, NET or NEC). Germline DNA testing is only recommended in the presence of a positive family history of MEN-1 or if multiple tumors are present in the absence of atrophic gastritis in the rare instances when MEN-1 diagnosis has not been done previously. Genetic analysis should also be performed in suspected cases of MEN-1. Genetic testing when performed should include mutational screening and sequencing, allowing for analysis of the entire coding gene and splice sites and genetic counseling should be sought prior to testing in all patients. Informed consent is mandatory prior to genetic testing. Somatic (tumor) DNA testing is not recommended.

Duodenal Neuroendocrine Tumors

d-NENs demonstrate light microscopic features typical of GI NETs in having trabecular, acinar, ribbon or cribriform structures which are uniform, have few mitosis, little necrosis and are separated by stroma [3, 7, 54, 55]. On silver staining 75–80% of d-NENs are argyrophilic [7, 8, 54, 55], they are usually argentaffin-negative (0–12% positive) [7, 8, 54], 75–100% show positivity for CgA [6–8, 41, 58], 80–100% for NSE [7, 8, 41, 59] and 91% for Leu-7 [8]. Greater than 85% of d-NENs synthesize GI peptides/amines and 40 ± 16% (7 series) synthesize hormones/amines [6, 7]. Their relative frequency is: gastrinomas (48%), somatostatinomas (43%), non-functioning serotonin-containing tumors (27%), non-functioning calcitonin-containing tumors (9%), NEC G3, and gangliocytic paragangliomas [6]. d-NENs uncommonly (<5%) produce insulin, PP, glucagon or ACTH.

Duodenal somatostatinomas tend to occur periampullary and histologically they frequently contain psammoma bodies (49–68%) [6, 8, 41, 56–59]. This is in contrast to other d-NENs, which uncommonly contain psammoma bodies (4.8%) [6, 42, 52, 55–59, 112].

Duodenal gangliocytic paragangliomas contain epithelial (with PP and somatostatin cells), ganglia, and spindle cells [6, 57, 113]. They characteristically contain gangliocytic differentiation and S-100 protein-immunoreactive Schwann cells [57, 113]. They also show positive staining for NSE in 94–100%, PGP 9.5 in 100%, synaptophysin in 94–100%, S-100 in 90%, PP in 75–92%, serotonin in 48–69%, CgA in most series in 10–15% and in-

frequently (<1%) calcitonin, gastrin or ACTH [6, 71, 113, 114]. Poorly differentiated non-functional duodenal carcinomas characteristically invade the muscularis propria, metastasize to lymph nodes and more distant sites and show features of other NEC G3. Patients with a d-NEN with MEN-1, a family history suggestive of MEN-1 or with multiple d-NENs should be considered for germline DNA testing for MEN-1 (following genetic counseling).

Minimal Consensus Statement on Pathology and Genetics

50–75% of d-NENs are well-differentiated NETs, 25–50% well-differentiated carcinomas and <1–3% NEC G3. All d-NENs should have routine histology with hematoxylin and eosin staining, as well as staining for CgA, and synaptophysin. S-100 staining should be performed on suspected gangliocytic paragangliomas and gastrin, somatostatin and serotonin if the clinical setting is suggestive. d-NENs should have a mitotic index determined by mitotic counting and a Ki67 to assess proliferative rate. Cytology is not routinely recommended.

Patients with a d-NEN with MEN-1, a family history suggestive of MEN-1 or with multiple d-NENs should be considered for germline DNA testing for MEN-1 (following genetic counseling).

Therapeutic Approaches

Gastric Neuroendocrine Neoplasms

In patients with type 1 gastric carcinoids, conservative management based on endoscopic follow-up and lesion resection should be preferred [28, 116]. It is recommended to remove all ECLomas whenever possible, however, nothing suggests that the evolution is less favorable in patients with tumors <1 cm left in place. In case of polyps >1 cm, EUS should be performed to assess wall and lymph nodal invasion before polypectomy by snare or endoscopic mucosal resection (EMR). Surgery should be performed in case of involvement beyond submucosa, or positive margin after EMR (local resection and antrectomy or total gastrectomy depending on tumor histological features, invasion and localization). Surgery should also be performed in the presence of lymph nodal or distant disease spread, and poorly differentiated neoplasms [28]. Indications to treatment by somatostatin analogs (SSA) or surgical antrectomy to suppress hypergastrinemia and limit ECL growth are still debated. SSA proved good antiproliferative properties, but their role in patients with type 1 g-NENs should be proposed only according to expert opinion [117–119].

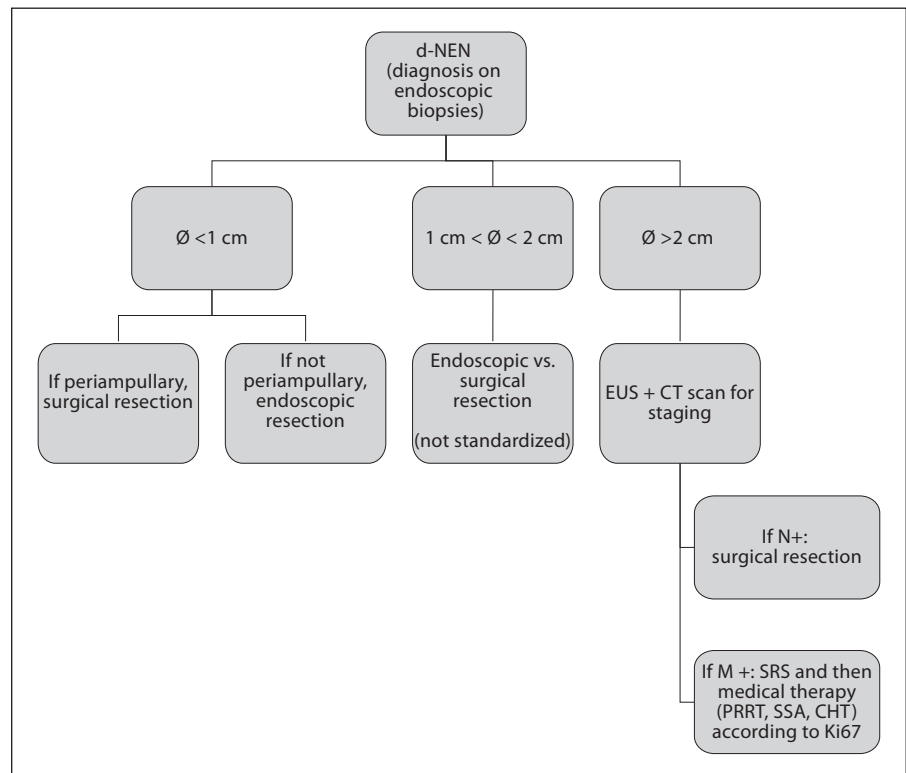


Fig. 1. Management of d-NENs.

For type 2 g-NENs, only local excision is recommended, and the presence of multiple tumors per se does not influence surgical management. In patients with type 3 tumors, surgical treatment should not differ from that of gastric adenocarcinomas, based on surgery (partial or total gastrectomy with lymph node dissection, with the same indications of gastric adenocarcinoma) and chemotherapy.

Minimal Consensus Statements on Therapeutic Approaches

In type 1 tumors, endoscopic management with lesion resection should be preferred. If polyps are >1 cm, EUS should be performed before excision by snare or EMR. Surgery should be limited to the cases of invasion beyond submucosa, metastases and poorly differentiated lesions. Gastrin suppression by surgical (i.e. antrectomy) or medical (i.e. SSA) is debatable. More radical surgery is required if lymph nodes are positive. In type 2, only local excision is recommended. The presence of multiple tumors does not per se influence surgical management. In type 3, treatment is similar to gastric adenocarcinoma, based on surgery and chemotherapy.

Duodenal Neuroendocrine Neoplasms

Management of d-NENs is shown in figure 1. Potential curative resection is possible in most patients with d-NENs because only $9 \pm 6\%$ (5 series) [6] have distant metastases at diagnosis with the remainder having either no metastases or a primary with lymph node metastases (40–60%) [3, 6, 7, 96, 100, 101, 109, 126]. If polyps are >1 cm, EUS should be performed before excision by snare or EMR. Numerous surgical/endoscopic methods have been reported to be effective at removing d-NENs, including endoscopic removal by snare or stripping; laparoscopic removal; transduodenal local excision or aggressive resection by a pancreaticoduodenectomy using either a Whipple resection or a pylorus-sparing pancreaticoduodenectomy [46, 59, 86, 88, 97, 120–131]. The optimal method for removing d-NENs remains unclear because their natural history is still largely unknown. In addition, the long-term relative results of resection performed with endoscopy, laparoscopy, transduodenal local resection or by pancreaticoduodenectomy have not yet been determined. Finally, the sensitivity of available tumor imaging modalities in assessing local progression pre- or postresection has not been determined, primarily because of the low frequency of these tumors [46, 75, 86, 97, 131].

All d-NETs should be removed unless in the presence of distant metastases or of medical conditions that markedly limit life expectancy or increase surgical risk. Small d-NENs should be removed by endoscopy if there is no evidence of lymph node metastases on tumor localization studies and preferably endoscopic ultrasound examination. However, if the d-NEN is in the periampullary region, local surgical resection may be required with lymphadenectomy or picking. Large d-NENs (i.e. >2 cm) or d-NETs of any size with lymph node metastases should be treated surgically with local resection (1st part duodenum), distal duodenectomy (4th part duodenum) or pancreaticoduodenectomy (frequently required in the 2nd and 3rd part of the duodenum). Treatment of intermediate size d-NENs (i.e. 1–2 cm) is controversial with some recommending endoscopic removal if no lymph node metastases are present on tumor localization studies (multislice CT scan/MRI, endoscopic ultrasound), whereas others recommend surgical treatment of these tumors [46, 59, 75, 86, 97]. With ampullary NENs, a number of studies report no correlation between the NEN size and the presence of malignancy [44–46, 73] and thus a pancreaticoduodenectomy is generally recommended for these tumors.

In the uncommon patient with a d-NEN who has hepatic metastases that are potentially resectable without distant metastases and no medical conditions markedly limiting life expectancy or increasing surgical risk, surgical resection and/or ablative therapy should be considered.

For the <10% of patients with functional hormonal syndromes due to a d-NEN, appropriate specific therapy for the hormone excess state should be instituted. Specifically, treatment of the acid hypersecretion with proton pump inhibitors in patients with ZES, treatment with SSA for carcinoid syndrome, and treatment of ectopic Cushing's syndrome medically or by adrenalectomy. For patients with advanced metastatic disease, interferon- α can be attempted, however, experience is limited. For patients with progressive advanced metastatic disease or with symptomatic diffuse metastatic disease, the combination of streptozotocin and 5-fluorouracil/doxorubicin is recommended in tumors with a low to moderate proliferative rate. Cisplatin/carboplatin plus etoposide is recommended in such patients with NEC. For patients with metastatic/inoperable disease with no other options, peptide receptor radionuclide therapy (PRRT) should be considered if the SRS is positive. Although there is extensive experience with this therapy with other GI NENs, especially with lutetium-177- or yttrium-90-labeled SSA [132–136], there is minimal experience specifically with d-NENs.

Minimal Consensus Statements on Therapeutic Approaches

All d-NENs should be removed unless in the presence of distant metastases or of medical conditions that markedly limit life expectancy or increase surgical risk. Small d-NENs (≤ 1 cm) can be locally resected by endoscopy. However, if the d-NEN is in the periampullary region, local surgical resection may be required with lymphadenectomy or picking. Large d-NENs (i.e. >2 cm) or d-NENs of any size with lymph node metastases should be treated surgically. In the uncommon patient with a d-NEN who has hepatic metastases that are potentially resectable without distant metastases and no medical conditions markedly limiting life expectancy or increasing surgical risk, surgical resection and/or ablative therapy should be considered.

For the <10% of patients with functional hormonal syndromes, appropriate specific therapy for the hormone excess state should be instituted (proton pump inhibitors in patients with ZES, SSA for carcinoid syndrome, and treatment of ectopic Cushing's syndrome medically or by adrenalectomy).

Medical Antiproliferative Treatment in Advanced Disease

Treatment of advanced disease is updated in a separate and comprehensive chapter [137]. In patients with gastric carcinoids, SSA have been shown to exert antiproliferative effects in animals and in man, however, data is not available in cases of liver metastases. SSA may be of value also in subgroups of patients with slowly progressive low proliferative NET (G1) of gastroduodenal origin and its use is supported by literature data on retrospective and non-randomized prospective trials in more than 500 patients [137–141]. Combinations of etoposide and cisplatin are indicated in metastatic G3 NE carcinomas regardless of the origin of the primary [137]. For patients with well-differentiated progressive advanced metastatic disease or with symptomatic diffuse metastatic disease, chemotherapy or PRRT should be considered. Although there is extensive experience with this therapy with other GI NETs, especially with lutetium-177- or yttrium-90-labeled SSA [132–136], there is minimal experience specifically with d-NENs.

Minimal Statement on Medical Treatment in Advanced Disease

Medical antiproliferative treatment options include SSA and PRRT. SSA are preferred for G1 tumors. Chemotherapy is recommended to treat G3 tumors, with combinations of cisplatin and etoposide. The early combination use of SSA and IFN for antiproliferative purposes is not recommended.

Follow-Up

Gastric Neuroendocrine Neoplasms

As type 1 g-NETs are recurring disease, endoscopic follow-up should be based on controls every 12 months for recurring patients, and any 24 months for not-recurring cases [28]. In case of lesions found during follow-up, they should be resected through endoscopy if possible; at any endoscopic control, a complete gastric map with multiple biopsies on normal gastric mucosa, in addition to polyps, would allow a better definition of ECL status and gastric atrophy grade [28, 79]. Clinical controls and laboratory monitoring should be performed in parallel to endoscopic procedure, also measuring iron and vitamin B₁₂ rate, thus prescribing a support therapy in case of deficiency [28]. In case of type 2 tumors, endoscopy should be repeated yearly. In patients with type 3 tumors, follow-up should depend on tumor subtype and is confident with program suggested for gastric adenocarcinoma. Follow-up should include radiological investigations (CT scan/MRI) and CgA.

Minimal Consensus Statements on Follow-Up

As type 1 gastric carcinoids are a recurring disease, endoscopic follow-up should be based on controls every 12 months for recurring patients, and any 24 months for not-recurring cases. In case of lesions found during follow-up, they should be resected through endoscopy if possible; at any endoscopic control, a complete gastric map with multiple biopsies on normal gastric mucosa, in addition to polyps, would allow a better definition of ECL status and gastric atrophy grade. Clinical controls and laboratory monitoring should be performed in parallel to endoscopic procedure, also measuring iron and vitamin B₁₂ rate. In type 2 tumors, endoscopy should be repeated yearly, while for type 3, after gastrectomy, it should follow control programs indicated for gastric adenocarcinomas.

Duodenal Neuroendocrine Neoplasms

In patients with a non-functional d-NEN completely removed at endoscopy, follow-up endoscopic examinations, abdominal ultrasound or multislice CT scan and plasmatic CgA levels are recommended at 6, 24 and 36 months. In patients with postsurgical resection, multislice CT scan, SRS and CgA levels are recommended at 6 and 12 months, then yearly for at least 3 years. If any abnormalities are detected, EUS should be performed. For patients with unresectable advanced metastatic disease, if no treatment is given because the disease is not progressive or symptomatic, the patient should be re-evaluated at 3- to 6-month intervals by CgA, multislice CT scan and/or ultrasound and SRS. For patients with metastatic/inopera-

ble disease receiving antitumor treatment (chemotherapy, interferon- α , PRRT), follow-up needs to be dictated by the protocol used and expected toxicities.

Minimal Consensus Statement on Follow-Up

In patients with a non-functional d-NEN completely removed at endoscopy, follow-up endoscopic examinations, abdominal ultrasound or CT scan and plasma CgA levels are recommended at 6, 24 and 36 months. In patients with postsurgical resection, multislice CT scan, SRS and CgA levels are recommended at 6 and 12 months, then yearly for at least 3 years. For patients with unresectable advanced metastatic disease, if no treatment is given because the disease is not progressive or symptomatic, the patient should be re-evaluated at 3- to 6-month intervals by CgA, multislice CT scan and/or ultrasound and SRS.

Acknowledgement

The authors are grateful to Dr. Elettra Merola, (Department of Digestive and Liver Disease, Ospedale S. Andrea, Rome, Italy) and thank her for her precious contribution to this paper.

Complete List of Participants

List of Participants of the Consensus Conference on the 2011 Consensus Guidelines for the Management of Patients with Digestive Neuroendocrine Tumors: An Update
Martin Anlauf, Germany (Martin.Anlauf@gmx.de)
Rudolf Arnold, Germany (arnoldr@staff.uni-marburg.de)
Detlef Bartsch, Germany (bartsch@med.uni-marburg.de)
Eric Baudin, France (baudin@igr.fr)
Richard Baum, Germany (info@rpbaum.de)
Maria Luisa Brandi, Italy (m.brandi@dmi.unifi.it)
Guillaume Cadiot, France (gcadiot@chu-reims.fr)
Frederico Costa, Brazil (frederico.costa@hsl.org.br)
Martyn Caplin, UK (m.caplin@medsch.ucl.ac.uk)
Anne Couvelard, France (anne.couvelard@bjn.aphp.fr)
Wouter de Herder, The Netherlands (w.w.deherder@erasmusmc.nl)
Gianfranco Delle Fave, Italy (gianfranco.dellefave@uniroma1.it)
Timm Denecke, Germany (timm.denecke@charite.de)
Barbro Eriksson, Sweden (barbro.eriksson@medsci.uu.se)
Massimo Falconi, Italy (massimo.falconi@univr.it)
Thomas Gress, Germany (gress@med.uni-marburg.de)
David Gross, Israel (gross@vms.huji.ac.il)
Ashley Grossman, UK (a.b.grossman@qmul.ac.uk)
Robert Jensen, USA (robertj@bdg10.niddk.nih.gov)
Gregory Kaltsas, Greece (gkaltsas@endo.gr)
Fahrettin Kelestimur, Turkey (fktimur@erciyes.edu.tr)
Reza Kianmanesh, France (reza.kianmanesh@lmr.ap-hop-paris.fr)
Günter Klöppel, Germany (guenter.kloepfel@alumni.uni-kiel.de)
Klaus-Jochen Klose, Germany (klose@med.uni-marburg.de)
Ulrich Knigge, Denmark (knigge@mfi.ku.dk)
Paul Komminoth, Switzerland (paul.komminoth@triemli.stzh.ch)
Beata Kos-Kudla, Poland (beatakos@ka.onet.pl)

Eric Krenning, The Netherlands (e.p.krenning@erasmusmc.nl)
Dik Kwekkeboom, The Netherlands
(d.j.kwekkeboom@erasmusmc.nl)
Jose Manuel Lopes, Portugal (jmlopes@ipatimup.pt)
Bruno Niederle, Austria (bruno.niederle@meduniwien.ac.at)
Ola Nilsson, Sweden (ola.nilsson@llcr.med.gu.se)
Kjell Öberg, Sweden (kjell.oberg@medsci.uu.se)
Juan O'Connor, Argentina (juanocconnor@hotmail.com)
Dermot O'Toole, Ireland (dermot.otoole@tcd.ie)
Ulrich-Frank Pape, Germany (ulrich-frank.pape@charite.de)
Mauro Papotti, Italy (mauro.papotti@unito.it)
Andreas Pascher, Germany (andreas.pascher@charite.de)
Marianne Pavel, Germany (marianne.pavel@charite.de)
Aurel Perren, Switzerland (aurel.perren@pathology.unibe.ch)
Ursula Plöckinger, Germany (ursula.ploekinger@charite.de)
Guido Rindi, Italy (guido.rindi@rm.unicatt.it)

Philippe Ruszniewski, France
(philippe.ruszniewski@bjn.aphp.fr)
Ramon Salazar, Spain (ramonsalazar@iconcologia.net)
Hironobu Sasano, Japan (hsasano@patholo2.med.tohoku.ac.jp)
Alain Sauvanet, France (alain.sauvanet@bjn.aphp.fr)
Jean-Yves Scoazec, France (jean-yves.scoazec@chu-lyon.fr)
Thomas Steinmüller, Germany
(t.steinmueller@drk-kliniken-westend.de)
Anders Sundin, Sweden (anders.sundin@radiol.uu.se)
Babs Taal, The Netherlands (b.taal@nki.nl)
Paola Tomassetti, Italy (paola.tomassetti@unibo.it)
Eric Van Cutsem, Belgium (eric.vancutsem@uzleuven.be)
Marie-Pierre Vullierme, France
(marie-pierre.vullierme@bjn.aphp.fr)
Bertram Wiedenmann, Germany
(bertram.wiedenmann@charite.de)

References

- 1 Ruszniewski P, Delle Fave G, Cadiot G, Komminoth P, Chung D, Kos-Kudla B, et al: Well-differentiated gastric tumors/carcinomas. *Neuroendocrinology* 2006;84:158–164.
- 2 Jensen RT, Rindi G, Arnold R, Lopes JM, Brandi ML, Bechstein WO, et al: Well-differentiated duodenal tumor/carcinoma (excluding gastrinomas). *Neuroendocrinology* 2006;84:165–172.
- 3 Kloppel G, Perren A, Heitz PU: The gastroenteropancreatic neuroendocrine cell system and its tumors: the WHO classification. *Ann NY Acad Sci* 2004;1014:13–27.
- 4 Attanoos R, Williams GT: Epithelial and neuroendocrine tumors of the duodenum. *Semin Diagn Pathol* 1991;8:149–162.
- 5 Jensen RT, Doherty GM: Carcinoid tumors and the carcinoid syndrome; in DeVita VT Jr, Hellman S, Rosenberg SA (eds): *Cancer: Principles and Practice of Oncology*. Philadelphia, Lippincott Williams & Wilkins, 2001, pp 1813–1833.
- 6 Hoffmann KM, Furukawa M, Jensen RT: Duodenal neuroendocrine tumors: classification, functional syndromes, diagnosis and medical treatment. *Best Pract Res Clin Gastroenterol* 2005;19:675–697.
- 7 Soga J, Yakuwa Y: Duodenal carcinoids: a statistical evaluation of 635 cases collected from the literature. *J Exp Clin Cancer Res* 1996;15:3–10.
- 8 Burke AP, Federspiel BH, Sobin LH, Shekitka KM, Helwig EB: Carcinoids of the duodenum. A histologic and immunohistochemical study of 65 tumors. *Am J Surg Pathol* 1989;13:828–837.
- 9 Niederle MB, Hackl M, Kaserer K, et al: Gastroenteropancreatic neuroendocrine tumours: the current incidence and staging based on the WHO and European Neuroendocrine Tumour Society classification: an analysis based on prospectively collected parameters. *Endocr Relat Cancer* 2010;17:909–918.
- 10 Bordi C: Gastric carcinoids. *Ital J Gastroenterol Hepatol* 1999;31(suppl 2):S94–S97.
- 11 Rindi G, Luinetti O, Cornaggia M, et al: Three subtypes of gastric argyrophil carcinoid and the gastric neuroendocrine carcinoma: a clinicopathologic study. *Gastroenterology* 1993;104:994–1006.
- 12 Rindi G, Bordi C, Rappel S, et al: Gastric carcinoids and neuroendocrine carcinomas: pathogenesis, pathology, and behavior. *World J Surg* 1996;20:168–172.
- 13 Borch K, Renvall H, Liedberg G: Gastric endocrine cell hyperplasia and carcinoid tumors in pernicious anemia. *Gastroenterology* 1985;88:638–648.
- 14 Solcia E, Bordi C, Creutzfeldt W, et al: Histopathological classification of nonantral gastric endocrine growths in man. *Digestion* 1988;41:185–200.
- 15 Carney JA, Go VL, Fairbanks VF, et al: The syndrome of gastric argyrophil carcinoid tumors and nonantral gastric atrophy. *Ann Intern Med* 1983;99:761–766.
- 16 Bordi C, Yu JY, Baggi MT, et al: Gastric carcinoids and their precursor lesions. A histologic and immunohistochemical study of 23 cases. *Cancer* 1991;67:663–672.
- 17 Sjoblom SM, Sipponen P, Karonen SL, et al: Mucosal argyrophil endocrine cells in pernicious anaemia and upper gastrointestinal carcinoid tumours. *J Clin Pathol* 1989;42:371–377.
- 18 Stockbrugger RW, Menon GG, Beilby JO, et al: Gastroscopic screening in 80 patients with pernicious anaemia. *Gut* 1983;24:1141–1147.
- 19 Gough DB, Thompson GB, Crotty TB, et al: Diverse clinical and pathologic features of gastric carcinoid and the relevance of hypergastrinemia. *World J Surg* 1994;18:473–480.
- 20 Rappel S, Altendorf-Hofmann A, Stolte M: Prognosis of gastric carcinoid tumours. *Digestion* 1995;56:455–462.
- 21 Modlin IM, Gilligan CJ, Lawton GP, et al: Gastric carcinoids. The Yale Experience. *Arch Surg* 1995;130:250–256.
- 22 Wilander E, El-Salhy M, Pitkanen P: Histopathology of gastric carcinoids: a survey of 42 cases. *Histopathology* 1984;8:183–193.
- 23 Thomas RM, Baybick JH, Elsayed AM, et al: Gastric carcinoids: an immunohistochemical and clinicopathologic study of 104 patients. *Cancer* 1994;73:2053–2058.
- 24 Cattan D, Roucayrol AM, Launay JM: Fundic endocrine disease of fundic atrophic gastritis with achlorhydria. I. Serum gastrin and fundic endocrine hyperplasia relationship: reality and significance. *Gastroenterol Clin Biol* 1991;15:30C–35C.
- 25 Vannella L, Sbrozzi-Vanni A, Lahner E, et al: Development of type I gastric carcinoid in patients with chronic atrophic gastritis. *Aliment Pharmacol Ther* 2011;33:1361–1369.
- 26 Borch K, Ahren B, Ahlman H, et al: Gastric carcinoids: biologic behavior and prognosis after differentiated treatment in relation to type. *Ann Surg* 2005;242:64–73.
- 27 Marignani M, Delle Fave G, Mecarocci S, et al: High prevalence of atrophic body gastritis in patients with unexplained microcytic and macrocytic anemia. A prospective screening study. *Am J Gastroenterol* 1999;94:766–772.
- 28 Merola E, Sbrozzi-Vanni A, Panzuto F, et al: Type I gastric carcinoids: a prospective study on endoscopic management and recurrence rate. *Neuroendocrinology* 2011 (E-pub ahead of print).

- 29 Rindi G, Arnold R, Bosman FT, et al: Nomenclature and classification of neuroendocrine neoplasms of the digestive system; in Bosman FT, et al (eds): WHO Classification of Tumours of the Digestive System. Lyon, IARC Press, 2010, pp 13–14.
- 30 La Rosa S, Inzani F, Vanoli A, et al: Histologic characterization and improved prognostic evaluation of 209 gastric neuroendocrine neoplasms. *Hum Pathol* 2011;42:1373–1384.
- 31 Lehy T, Cadiot G, Mignon M, et al: Influence of multiple endocrine neoplasia type 1 on gastric endocrine cells in patients with the Zollinger-Ellison syndrome. *Gut* 1992;33:1275–1279.
- 32 Cadiot G, Laurent-Puig P, Thuille B, et al: Is the multiple endocrine neoplasia type 1 gene a suppressor for fundic argyrophil tumors in the Zollinger-Ellison syndrome? *Gastroenterology* 1993;105:579–582.
- 33 Gibril F, Schumann M, Pace A, et al: Multiple endocrine neoplasia type 1 and Zollinger-Ellison syndrome: a prospective study of 107 cases and comparison with 1,009 cases from the literature. *Medicine (Baltimore)* 2004;83:43–83.
- 34 Norton JA, Melcher ML, Gibril F, et al: Gastric carcinoid tumors in multiple endocrine neoplasia-I patients with Zollinger-Ellison syndrome can be symptomatic, demonstrate aggressive growth, and require surgical treatment. *Surgery* 2004;136:1267–1274.
- 35 Cadiot G, Vissuzaine C, Potet F, et al: Fundic argyrophil carcinoid tumor in a patient with sporadic-type Zollinger-Ellison syndrome. *Dig Dis Sci* 1995;40:1275–1278.
- 36 Rindi G, Azzoni C, La Rosa S, et al: ECL cell tumor and poorly differentiated endocrine carcinoma of the stomach: prognostic evaluation by pathological analysis. *Gastroenterology* 1999;116:532–542.
- 37 Modlin IM, Lye KD, Kidd M: Carcinoid tumors of the stomach. *Surg Oncol* 2003;12:153–172.
- 38 Williams ED, Sandler M: The classification of carcinoid tumours. *Lancet* 1963;1:238–239.
- 39 Modlin IM, Lye KD, Kidd M: A 5-decade analysis of 13,715 carcinoid tumors. *Cancer* 2003;97:934–959.
- 40 Spinazzola AJ, Gillesby WJ: Primary malignant neoplasms of the duodenum: report of twelve cases. *Am Surg* 1963;29:405–412.
- 41 Witzigmann H, Loracher C, Geissler F, Wagner T, Tannapfel A, Uhlmann D, Caca K, Hauss J, Hehl A: Neuroendocrine tumours of the duodenum: clinical aspects, pathomorphology and therapy. *Langenbecks Arch Surg* 2002;386:525–533.
- 42 Bornstein-Quevedo L, Gamboa-Dominguez A: Carcinoid tumors of the duodenum and ampulla of Vater: a clinicomorphologic, immunohistochemical, and cell kinetic comparison. *Hum Pathol* 2001;32:1252–1256.
- 43 Walton GF, Gibbs ER, Spencer GO, Laws HL: Carcinoid tumors of the ampulla of Vater. *Am Surg* 1997;63:302–304.
- 44 Hatzitheoklitos E, Buchler MW, Friess H, Poch B, Ebert M, Mohr W, et al: Carcinoid of the ampulla of Vater: clinical characteristics and morphologic features. *Cancer* 1994;73:1580–1588.
- 45 Clements WM, Martin SP, Stemmerman G, Lowy AM: Ampullary carcinoid tumors: rationale for an aggressive surgical approach. *J Gastrointest Surg* 2003;7:773–776.
- 46 Hartel M, Wente MN, Sido B, Friess H, Buchler MW: Carcinoid of the ampulla of Vater. *J Gastroenterol Hepatol* 2005;20:676–681.
- 47 Soga J, Yakuwa Y: Somatostatinoma/inhibitory syndrome: a statistical evaluation of 173 reported cases as compared to other pancreatic endocrinomas. *J Exp Clin Cancer Res* 1999;18:13–22.
- 48 Taccagni GL, Carlucci M, Sironi M, Cantaboni A, DiCarlo V: Duodenal somatostatinoma with psammoma bodies: an immunohistochemical and ultrastructural study. *Am J Gastroenterol* 1986;81:33–37.
- 49 Green BT, Rockey DC: Duodenal somatostatinoma presenting with complete somatostatinoma syndrome. *J Clin Gastroenterol* 2001;33:415–417.
- 50 Swinburn BA, Yeong ML, Lane MR, Nicholson GI, Holdaway IM: Neurofibromatosis associated with somatostatinoma: a report of two patients. *Clin Endocrinol (Oxf)* 1988;28:353–359.
- 51 Jensen RT: Endocrine tumors of the pancreas; in Yamada T, Alpers DH, Kaplowitz N, Laine L, Owyang C, Powell DW (eds): *Textbook of Gastroenterology*. Philadelphia, Lippincott Williams & Wilkins, 2003, pp 2108–2146.
- 52 Weichert RF 3rd, Roth LM, Kremenz ET, Hewitt RL, Drapanas T: Carcinoid-islet cell tumors of the duodenum. *Am J Surg* 1971;121:195–205.
- 53 Lasson A, Alwmark A, Nobin A, Sundler F: Endocrine tumors of the duodenum. Clinical characteristics and hormone content. *Ann Surg* 1983;197:393–398.
- 54 Alumets J, Sundler F, Falkmer S, Ljungberg O, Hakanson R, Martensson H, et al: Neurohormonal peptides in endocrine tumors of the pancreas, stomach, and upper small intestine. I. An immunohistochemical study of 27 cases. *Ultrastruct Pathol* 1983;5:55–72.
- 55 Stamm B, Hedinger CE, Saremaslani P: Duodenal and ampullary carcinoid tumors. A report of 12 cases with pathological characteristics, polypeptide content and relation to MEN-1 syndrome and von Recklinghausen's disease (neurofibromatosis). *Virchows Arch A Pathol Anat Histopathol* 1986;408:475–489.
- 56 Burke AP, Sobin LH, Federspiel BH, Shekitka KM, Helwig EB: Carcinoid tumors of the duodenum: a clinicopathologic study of 99 cases. *Arch Pathol Lab Med* 1990;114:700–704.
- 57 Capella C, Riva C, Rindi G, Usellini L, Chiaravalli A, Solcia E: Endocrine tumors of the duodenum and upper jejunum: a study of 33 cases with clinico-pathological characteristics and hormone content. *Hepatogastroenterology* 1990;37:247–252.
- 58 Heymann MF, Hamy A, Triau S, Miraille E, Toquet C, Chomarar H, Cohen C, Maitre F, Le Bodie MF: Endocrine tumors of the duodenum. A study of 55 cases relative to clinicopathological features and hormone content. *Hepatogastroenterology* 2004;51:1367–1371.
- 59 Soga J: Endocrinocarcinomas (carcinoids and their variants) of the duodenum. An evaluation of 927 cases. *J Exp Clin Cancer Res* 2003;22:349–363.
- 60 Thom AK, Norton JA, Axiotis CA, Jensen RT: Location, incidence and malignant potential of duodenal gastrinomas. *Surgery* 1991;110:1086–1093.
- 61 Norton JA, Alexander HR, Fraker DL, Venzon DJ, Jensen RT: Does the use of routine duodenotomy affect rate of cure, development of liver metastases or survival in patients with Zollinger-Ellison syndrome? *Ann Surg* 2004;239:617–626.
- 62 Norton JA, Jensen RT: Current surgical management of Zollinger-Ellison syndrome in patients without multiple endocrine neoplasia type 1. *Surg Oncol* 2003;12:145–151.
- 63 Gibril F, Jensen RT: Advances in evaluation and management of gastrinoma in patients with Zollinger-Ellison syndrome. *Curr Gastroenterol Rep* 2005;7:114–121.
- 64 Zogakis TG, Gibril F, Libutti SK, Norton JA, White DE, Jensen RT, Alexander HR: Management and outcome of patients with sporadic gastrinomas arising in the duodenum. *Ann Surg* 2003;238:42–48.
- 65 Jensen RT, Gardner JD: Gastrinoma; in Go VLW, DiMaggio EP, Gardner JD, Lebenthal E, Reber HA, Scheele GA (eds): *The Pancreas: Biology, Pathobiology and Disease*. New York, Raven Press, 1993, pp 931–978.
- 66 Weber HC, Venzon DJ, Lin JT, Fishbein VA, Orbuch M, Strader DB, et al: Determinants of metastatic rate and survival in patients with Zollinger-Ellison syndrome: a prospective long-term study. *Gastroenterology* 1995;108:1637–1649.
- 67 Yu F, Venzon DJ, Serrano J, Goebel SU, Doppman JL, Gibril F, Jensen RT: Prospective study of the clinical course, prognostic factors and survival in patients with longstanding Zollinger-Ellison syndrome. *J Clin Oncol* 1999;17:615–630.
- 68 Gibril F, Schumann M, Pace A, Jensen RT: Multiple endocrine neoplasia type 1 and Zollinger-Ellison syndrome: a prospective study of 107 cases and comparison with 1,009 patients from the literature. *Medicine* 2004;83:43–83.
- 69 Jensen RT: Management of the Zollinger-Ellison syndrome in patients with multiple endocrine neoplasia type 1. *J Intern Med* 1998;243:477–488.
- 70 Norton JA, Fraker DL, Alexander HR, Venzon DJ, Doppman JL, Serrano J, Goebel SU, Peghini P, Roy PK, Gibril F, Jensen RT: Surgery to cure the Zollinger-Ellison syndrome. *N Engl J Med* 1999;341:635–644.

- 71 Burke AP, Helwig EB: Gangliocytic paraganglioma. *Am J Clin Pathol* 1985;92:1-9.
- 72 Cohen T, Zweig SJ, Tallis A, Tuazon R, Reich M: Paraganglioneuroma of the duodenum: report of a case with radiographic findings, angiographic findings and a review of the literature. *Am J Gastroenterol* 1981;75:197-203.
- 73 Makhoul HR, Burke AP, Sobin LH: Carcinoid tumors of the ampulla of Vater: a comparison with duodenal carcinoid tumors. *Cancer* 1999;85:1241-1249.
- 74 Kirshbom PM, Kherani AR, Onaitis MW, Hata A, Kehoe TE, Feldman C, Feldman JM, Tyler DS: Foregut carcinoids: a clinical and biochemical analysis. *Surgery* 1999;126:1105-1110.
- 75 Zyromski NJ, Kendrick ML, Nagorney DM, Grant CS, Donohue JH, Farnell MB, Thompson GB, Farley DR, Sarr MG: Duodenal carcinoid tumors: how aggressive should we be? *J Gastrointest Surg* 2001;5:588-593.
- 76 Wang HY, Chen MJ, Yang TL, Chang MC, Chan YJ: Carcinoid tumor of the duodenum and accessory papilla associated with polycythemia vera. *World J Gastroenterol* 2005;11:3794-3796.
- 77 Amano S, Hazama F, Haebara H, Tsurusawa M, Kaito H: Ectopic ACTH-MSH producing carcinoid tumor with multiple endocrine hyperplasia in a child. *Acta Pathol Jpn* 1978;28:721-730.
- 78 Dayal Y, Tallberg KA, Nunnemacher G, DeLellis RA, Wolfe HJ: Duodenal carcinoids in patients with and without neurofibromatosis: a comparative study. *Am J Surg Pathol* 1986;10:348-357.
- 79 Annibale B, Azzoni C, Corleto VD, et al: Atrophic body gastritis patients with enterochromaffin-like cell dysplasia are at increased risk for the development of type I gastric carcinoid. *Eur J Gastroenterol Hepatol* 2001;13:1449-1456.
- 80 Cattani D, Roucayrol AM, Launay JM, et al: Serum gastrin and argyrophil cell hyperplasia relationships in fundic gastritis; in Hankanson R, Sunder F (eds): *The Stomach as an Endocrine Organ*. Amsterdam, Elsevier Science, 1991, pp 425-448.
- 81 Borch K, Renvall H, Liedberg G, et al: Relations between circulating gastrin and endocrine cell proliferation in the atrophic gastric fundic mucosa. *Scand J Gastroenterol* 1986;21:357-363.
- 82 Peracchi M, Gebbia C, Basilisco G, et al: Plasma chromogranin A in patients with autoimmune chronic atrophic gastritis, enterochromaffin-like cell lesions and gastric carcinoids. *Eur J Endocrinol* 2005;152:443-448.
- 83 Lehy T, Mignon M, Cadiot G, et al: Gastric endocrine cell behavior in Zollinger-Ellison patients upon long-term potent antisecretory treatment. *Gastroenterology* 1989;96:1029-1040.
- 84 Mignon M, Lehy T, Bonnefond A, et al: Development of gastric argyrophil carcinoid tumors in a case of Zollinger-Ellison syndrome with primary hyperparathyroidism during long-term antisecretory treatment. *Cancer* 1987;59:1959-1962.
- 85 Maton PN, Miller DL, Doppman JL, Collen MJ, Norton JA, Vinayek R, et al: Role of selective angiography in the management of Zollinger-Ellison syndrome. *Gastroenterology* 1987;92:913-918.
- 86 Mullen JT, Wang H, Yao JC, Lee JH, Perrier ND, Pisters PW, Lee JE, Evans DB: Carcinoid tumors of the duodenum. *Surgery* 2005;138:971-977.
- 87 Orbuch M, Doppman JL, Strader DB, Fishbeyn VA, Benya RV, Metz DC, Jensen RT: Imaging for pancreatic endocrine tumor localization: recent advances; in Mignon M, Jensen RT (eds): *Endocrine Tumors of the Pancreas: Recent Advances in Research and Management*. Front Gastrointest Res. Basel, Karger, 1995, vol 23, pp 268-281.
- 88 Norton JA, Doppman JL, Jensen RT: Curative resection in Zollinger-Ellison syndrome: results of a 10-year prospective study. *Ann Surg* 1992;215:8-18.
- 89 Alexander HR, Fraker DL, Norton JA, Bartlett DL, Tio L, Benjamin SB, et al: Prospective study of somatostatin receptor scintigraphy and its effect on operative outcome in patients with Zollinger-Ellison syndrome. *Ann Surg* 1998;228:228-238.
- 90 Frucht H, Doppman JL, Norton JA, Miller DL, Dwyer AJ, Frank JA, et al: Gastrinomas: comparison of MR imaging with CT, angiography and US. *Radiology* 1989;171:713-717.
- 91 Gibril F, Jensen RT: Diagnostic uses of radiolabelled somatostatin-receptor analogues in gastroenteropancreatic endocrine tumors. *Dig Liver Dis* 2004;36:S106-S120.
- 92 Acs G, McGrath CM, Gupta PK: Duodenal carcinoid tumor: report of a case diagnosed by endoscopic ultrasound-guided fine-needle aspiration biopsy with immunocytochemical correlation. *Diagn Cytopathol* 2000;23:183-186.
- 93 Yoshikane H, Tsukamoto Y, Niwa Y, Goto H, Hase S, Mizutani K, Nakamura T: Carcinoid tumors of the gastrointestinal tract: evaluation with endoscopic ultrasonography. *Gastrointest Endosc* 1993;39:375-383.
- 94 Dalenback J, Havel G: Local endoscopic removal of duodenal carcinoid tumors. *Endoscopy* 2004;36:651-655.
- 95 Yoshikane H, Suzuki T, Yoshioka N, Ogawa Y, Hamajima E, Hasegawa N, Hasegawa C: Duodenal carcinoid tumor: endosonographic imaging and endoscopic resection. *Am J Gastroenterol* 1995;90:642-644.
- 96 Yoshikane H, Goto H, Niwa Y, Matsui M, Ohashi S, Suzuki T, et al: Endoscopic resection of small duodenal carcinoid tumors with strip biopsy technique. *Gastrointest Endosc* 1998;47:466-470.
- 97 Norton JA, Jensen RT: Resolved and unresolved controversies in the surgical management of patients with Zollinger-Ellison syndrome. *Ann Surg* 2004;240:757-773.
- 98 Proye C, Malvaux P, Pattou F, Filoche B, Godchaux JM, Maunoury V, et al: Noninvasive imaging of insulinomas and gastrinomas with endoscopic ultrasonography and somatostatin receptor scintigraphy. *Surgery* 1998;124:1134-1144.
- 99 Ruszniewski P, Amouyal P, Amouyal G, Grange JD, Mignon M, Bouch O, Bernades P: Localization of gastrinomas by endoscopic ultrasonography in patients with Zollinger-Ellison syndrome. *Surgery* 1995;117:629-635.
- 100 Gibril F, Reynolds JC, Doppman JL, Chen CC, Venzon DJ, Termanini B, et al: Somatostatin receptor scintigraphy: its sensitivity compared with that of other imaging methods in detecting primary and metastatic gastrinomas: a prospective study. *Ann Intern Med* 1996;125:26-34.
- 101 Termanini B, Gibril F, Reynolds JC, Doppman JL, Chen CC, Stewart CA, et al: Value of somatostatin receptor scintigraphy: a prospective study in gastrinoma of its effect on clinical management. *Gastroenterology* 1997;112:335-347.
- 102 Gibril F, Doppman JL, Reynolds JC, Chen CC, Sutliff VE, Yu F, et al: Bone metastases in patients with gastrinomas: a prospective study of bone scanning, somatostatin receptor scanning, and MRI in their detection, their frequency, location and effect of their detection on management. *J Clin Oncol* 1998;16:1040-1053.
- 103 Meijer WG, van der Veer E, Jager PL, van der Jagt EJ, Piers BA, Kema IP, et al: Bone metastases in carcinoid tumors: clinical features, imaging characteristics, and markers of bone metabolism. *J Nucl Med* 2003;44:184-191.
- 104 Lebtahi R, Cadiot G, Delahaye N, Genin R, Daou D, Peker MC, Chosidow D, Faraggi M, Mignon M, LeGuludec D: Detection of bone metastases in patients with endocrine gastroenteropancreatic tumors: bone scintigraphy compared with somatostatin receptor scintigraphy. *J Nucl Med* 1999;40:1602-1608.
- 105 Hubalewska-Dydejczyk A, Szybinski P, Fross-Baron K, Mikolajczak R, Huszno B, Sowa-Staszczak A: ^{99m}Tc-EDDA/HYNIC-octreotate: a new radiotracer for detection and staging of NET. A case of metastatic duodenal carcinoid. *Nucl Med Rev Cent East Eur* 2005;8:155-156.
- 106 Taal BG, Smits M: Developments in diagnosis and treatment of metastatic midgut carcinoid tumors: a review. *Minerva Gastroenterol Dietol* 2005;51:335-344.
- 107 Oo TH, Aish LS, Schneider D, Hassoun H: Carcinoid tumor presenting with bone marrow metastases. *J Clin Oncol* 2003;21:2995-2996.

- 108 Zuetenhorst JM, Hoefnagel CA, Boot H, Valdes Olmos RA, Taal BG: Evaluation of ¹¹¹In-pentetreotide, ¹³¹I-MIBG and bone scintigraphy in the detection and clinical management of bone metastases in carcinoma disease. *Nucl Med Commun* 2002;23:735–741.
- 109 Goebel SU, Serrano J, Yu F, Gibril F, Venzon DJ, Jensen RT: Prospective study of the value of serum chromogranin A or serum gastrin levels in assessment of the presence, extent, or growth of gastrinomas. *Cancer* 1999;85:1470–1483.
- 110 Nikou GC, Toubanakis C, Nikolaou P, Giannatou E, Marinou K, Safioleas M, Karamanolis D: Gastrinomas associated with MEN-1 syndrome: new insights for the diagnosis and management in a series of 11 patients. *Hepatogastroenterology* 2005;52:1668–1676.
- 111 Solcia E, Kloppel G, Sobin LH: Histological typing of endocrine tumours; in Solcia E, Kloppel G, Sobin LH (eds): *Histological Typing of Endocrine Tumours*. International classification of Tumours, ed 2. Berlin, Springer, 2000.
- 112 Tanaka S, Yamasaki S, Matsushita S, Ozawa Y, Kurosaki A, Takeuchi K, Hoshihara Y, Doi T, Watanabe G, Kawaminami K: Duodenal somatostatinoma: a case report and review of 31 cases with special reference to the relationship between tumor size and metastasis. *Pathol Int* 2000;50:146–152.
- 113 Barbareschi M, Frigo B, Aldovini D, Leonard E, Cristina S, Falleni M: Duodenal gangliocytic paraganglioma. Report of a case and review of the literature. *Virchows Arch A Pathol Anat Histopathol* 1989;416:81–89.
- 114 Altavilla G, Chiarelli S, Fassina A: Duodenal periampullary gangliocytic paraganglioma: report of two cases with immunohistochemical and ultrastructural study. *Ultrastruct Pathol* 2001;25:137–145.
- 115 Sata N, Tsukahara M, Koizumi M, Yoshizawa K, Kurihara K, Nagai H, Someya T, Saito K: Primary small-cell neuroendocrine carcinoma of the duodenum: a case report and review of literature. *World J Surg Oncol* 2004;2:28.
- 116 Scherübl H, Cadiot G, Jensen RT, et al: Neuroendocrine tumors of the stomach (gastric carcinoids) are on the rise: small tumors, small problems? *Endoscopy* 2010;42:664–671.
- 117 Manfredi S, Pagenault M, de Lajarte-Thirouard AS, et al: Type 1 and 2 gastric carcinoid tumors: long-term follow-up of the efficacy of treatment with a slow-release somatostatin analogue. *Eur J Gastroenterol Hepatol* 2007;19:1021–1025.
- 118 Grozinsky-Glasberg S, Kaltsas G, Gur C, et al: Long-acting somatostatin analogues are an effective treatment for type 1 gastric carcinoid tumours. *Eur J Endocrinol* 2008;159:475–482.
- 119 Campana D, Nori F, Pezzilli R, et al: Gastric endocrine tumors type I: treatment with long-acting somatostatin analogs. *Endocr Relat Cancer* 2008;15:337–342.
- 120 Pyun DK, Moon G, Han J, Kim MH, Lee SS, Seo DW, Lee SK: A carcinoid tumor of the ampulla of Vater treated by endoscopic snare papillectomy. *Korean J Intern Med* 2004;19:257–260.
- 121 Bowers SP, Smith CD: Laparoscopic resection of posterior duodenal bulb carcinoid tumor. *Am Surg* 2003;69:792–795.
- 122 Perng CL, Lin HJ, Wang K, Lai CR, Lee SD: Treatment of duodenal carcinoid by strip biopsy. *J Clin Gastroenterol* 1995;20:168–171.
- 123 Sato T, Fukunaga T, Ohyama S, Ueno M, Oya M, Yamamoto J, et al: Endoscopic total layer resection with laparoscopic sentinel node dissection and defect closure for duodenal carcinoid. *Hepatogastroenterology* 2005;52:678–679.
- 124 Horsley GW, Golden BN: Carcinoid tumors of the duodenum. *Surg Gynecol Obstet* 1957;105:417–424.
- 125 Thompson GB, Van Heerden JA, Martin JK Jr, Schutt AJ, Ilstrup DM, Carney JA: Carcinoid tumors of the gastrointestinal tract: presentation, management, and prognosis. *Surgery* 1985;98:1054–1063.
- 126 Toyonaga T, Nakamura K, Araki Y, Shimura H, Tanaka M: Laparoscopic treatment of duodenal carcinoid tumor: wedge resection of the duodenal bulb under endoscopic control. *Surg Endosc* 1998;12:1085–1087.
- 127 Blanc P, Porcheron J, Pages A, Breton C, Mosnier JF, Balique JG: Laparoscopic excision of a duodenal neuroendocrine tumor. *Ann Chir* 2000;125:176–178.
- 128 Yamamoto C, Aoyagi K, Suekane H, Iida M, Hizawa K, Kuwano Y, et al: Carcinoid tumors of the duodenum: report of three cases treated by endoscopic resection. *Endoscopy* 1997;29:218–221.
- 129 Sugg SL, Norton JA, Fraker DL, Metz DC, Pisegna JR, Fishbeyn V, et al: A prospective study of intraoperative methods to diagnose and resect duodenal gastrinomas. *Ann Surg* 1993;218:138–144.
- 130 Norton JA, Doppman JL, Collen MJ, Harmon JW, Maton PN, Gardner JD, Jensen RT: Prospective study of gastrinoma localization and resection in patients with Zollinger-Ellison syndrome. *Ann Surg* 1986;204:468–479.
- 131 Yoshikane H, Tsukamoto Y, Niwa Y, Goto H, Hase S, Mizutani K, Nakamura T: Carcinoid tumors of the gastrointestinal tract: evaluation with endoscopic ultrasonography. *Gastrointest Endosc* 1993;39:375–383.
- 132 Krenning EP, Kwekkeboom DJ, Valkema R, Pauwels S, Kvols LK, de Jong M: Peptide receptor radionuclide therapy. *Ann NY Acad Sci* 2004;1014:234–245.
- 133 De Jong M, Kwekkeboom D, Valkema R, Krenning EP: Radiolabelled peptides for tumour therapy: current status and future directions. Plenary lecture at the EANM 2002. *Eur J Nucl Med Mol Imaging* 2003;30:463–469.
- 134 Kwekkeboom DJ, Mueller-Brand J, Paganelli G, Anthony LB, Pauwels S, Kvols LK, et al: Overview of results of peptide receptor radionuclide therapy with three radiolabeled somatostatin analogs. *J Nucl Med* 2005;46(suppl 1):62S–66S.
- 135 Valkema R, Pauwels S, Kvols LK, Barone R, Jamar F, Bakker WH, et al: Survival and response after peptide receptor radionuclide therapy with (⁹⁰Y-DOTA⁰,Tyr³)octreotide in patients with advanced gastroenteropancreatic neuroendocrine tumors. *Semin Nucl Med* 2006;36:147–156.
- 136 Kwekkeboom DJ, Teunissen JJ, Bakker WH, Kooij PP, de Herder WW, Feelders RA, et al: Radiolabeled somatostatin analog (¹⁷⁷Lu-DOTA⁰,Tyr³)octreotate in patients with endocrine gastroenteropancreatic tumors. *J Clin Oncol* 2005;23:2754–2762.
- 137 Pavel M, Baudin E, Couvelard A, Krenning E, Öberg K, Steinmüller T, et al: ENETS consensus guidelines for the management of patients with liver and other distant metastases from neuroendocrine neoplasms of foregut, midgut, hindgut, and unknown primary. *Neuroendocrinology* 2012;95:157–176.
- 138 Modlin IM, Pavel M, Kidd M, et al: Review article: somatostatin analogues in the treatment of gastroenteropancreatic neuroendocrine (carcinoid) tumours. *Aliment Pharmacol Ther* 2010;31:169–188.
- 139 Arnold R, Rinke A, Klose KJ, Müller HH, Wied M, Zamzow K, et al: Octreotide versus octreotide plus interferon in endocrine gastroenteropancreatic tumors: a randomized trial. *Clin Gastroenterol Hepatol* 2005;3:761–771.
- 140 Faiss S, Pape UF, Bohmig M, Dorffel Y, Mansmann U, Golder W, et al: International Lanreotide and Interferon Alfa Study Group: prospective, randomized, multicenter trial on the antiproliferative effect of lanreotide, interferon alfa, and their combination for therapy of metastatic neuroendocrine gastroenteropancreatic tumors – the International Lanreotide and Interferon Alfa Study Group. *J Clin Oncol* 2003;21:2689–2696.
- 141 Butturini G, Bettini R, Missiaglia E, Mantovani W, Dalai I, Capelli P, et al: Predictive factors of efficacy of the somatostatin analogue octreotide as first line therapy for advanced pancreatic endocrine carcinoma. *Endocr Relat Cancer* 2006;13:1213–1221.